

Supplementary Online Content

McCreary D, Omoyinmi E, Hong Y, et al. Development and validation of a targeted next-generation sequencing gene panel for children with neuroinflammation. *JAMA Netw Open*. 2019;2(10):e1914274. doi:10.1001/jamanetworkopen.2019.14274

eMethods. Additional Information

eTable 1. List of Laboratory Investigations Organized in Context of Routine Clinical Care for Patients With Suspected Neuroinflammation

eTable 2. Detailed List of Genes Included in Neuroinflammation Panel (NIP)

eTable 3. SureDesign Description of Probes for NIP

eTable 4. Regions Below the Depth of Coverage Threshold of 30X

eTable 5. List of Regions With More Baits Added to Improve Coverage

eTable 6. Clinical Features and Class 4 and 5 Genetic Variants Identified on Neuroinflammation Gene Panel (NIP) in Patients With Suspected Genetic Neuroinflammatory Disorders and Unknown Molecular Diagnoses

eTable 7. Clinical Features and Class 3 Genetic Variants Identified on Neuroinflammation Gene Panel (NIP) in 34 Patients With Suspected Genetic Neuroinflammatory Disorders and Unknown Molecular Diagnoses

eFigure. Further Tests in Patients With Isolated Neuroinflammation

This supplementary material has been provided by the authors to give readers additional information about their work.

eMethods. Additional Information

Granule release assay

The granule release assay was performed according to Wheeler et al. (2010). Peripheral blood mononuclear cells (PBMC) were stimulated with IL-2 overnight, and then incubated with FITC-conjugated anti-CD107a antibody alone, or with anti-CD3 antibody or PHA, for 2 h. Samples were analyzed by flow cytometry and gating on lymphocytes by forward/side scatter. CD107a expression was analyzed on cytotoxic T cells (CD8+ and CD3+) and on NK cells (CD56+ and CD3-), and the increase in percentage of CD107a+ cells between unstimulated and stimulated samples was calculated.

XIAP and SAP Protein expression.

Normal healthy control and whole blood was fixed and permeabilized using Intraprep/Intraperm (Beckman Coulter) according to manufacturer's protocol. An isotype IgG (BD Biosciences), anti-SAP (Abnova) or anti-XIAP (BD Biosciences) was added at to each tube, incubated 15 minutes room temperature, washed with PBS/0.1mM EDTA/1%BSA followed by staining with anti-CD3, anti-CD56 and anti-CD8 (BD Bioscience) for 10 minutes at room temperature. Samples were then washed, fixed (Cell Fix, BD Bioscience) and acquired on a FACsCalibur (BD Bioscience). Using Celle Quest software (BD Bioscience), sequential gating was used to identify the CD8 population and then histogram analyses with SAP and XIAP overlaying the isotype. Controls have >50% positivity for SAP and XIAP.

Bioinformatics parameters used for both SureCall and Genesis pipelines.

Agilent SureCall (Version 4.0.1.46) analysis parameters:

SNPPET caller in SureCall was used to identify single nucleotide polymorphisms (SNPs), multiple nucleotide polymorphisms (MNP). The parameters that SureCall uses to identify SNPs, MNPs, and indels are:

- QC Metric applied: true
- Report Regions Having Read Depth Below: 20
- Enable Trimming: true
- Quality Threshold for Trimming: 5
- Minimum Read Length Fraction: 30
- Maximum Read Length Fraction: 100
- Aligner applied: true
- Illumina: BWA MEM
- Mismatch Penalty: 4.0
- Base Quality Encoding: Auto Detect
- Score Threshold for a Match: 1.0
- Maximum Number of Mismatches: 2
- Output Filter: Unique Best Hits
- Constraint for maximal gap length: 100
- Minimum matching seed length: 19
- Remove Duplicates: true
- Region Padding applied: true
- Region Padding: 100
- BAQ SNP Caller applied: false
- SNPPET SNP Caller applied: true
- Quality value threshold: 0.3
- Use base quality recalibration: false

- Minimum mapping quality for read: 30
 - Minimum quality for base: 30
 - Report multiple Alleles at a locus: false
 - Quality value threshold (low frequency): 100
 - Minimum Allele Frequency: 0.03
 - Minimum number of reads supporting variant allele: 10
- Parameters for SureCall data analysis for Copy Number Variation.*

- QC Metric applied: true
- Report Regions Having Read Depth Below: 20
- Enable Trimming: true
- Quality Threshold for Trimming: 5
- Minimum Read Length Fraction: 30
- Maximum Read Length Fraction: 100
- Aligner applied: true
- Illumina: BWA MEM
- Mismatch Penalty: 4.0
- Base Quality Encoding: Auto Detect
- Score Threshold for a Match: 1.0
- Maximum Number of Mismatches: 2
- Output Filter: Unique Best Hits
- Constraint for maximal gap length: 100
- Minimum matching seed length: 19
- Remove Duplicates: true
- Region Padding applied: true
- Region Padding: 100
- BAQ SNP Caller applied: false
- SNPPEP SNP Caller applied: true
- Quality value threshold: 0.3
- Use base quality recalibration: false
- Minimum mapping quality for read: 30
- Minimum quality for base: 30
- Report multiple Alleles at a locus: false
- Quality value threshold (low frequency): 100
- Minimum Allele Frequency: 0.01
- Minimum number of reads supporting variant allele: 10
- Minimum number of read pairs per barcode: 2
- Minimum number of reads supporting Denovo variant: 10
- Denovo variant quality: 0
- Denovo variant genotype quality: 10
- SNP Filter: true
- Absolute difference in max base quality observed for variant and wild type reads: 20:20:20
- Mutation Impact: Default
- Version of Annotation: V3

Parameters for Genesis data analysis

Genesis is an in-house pipeline, developed at NE Thames Regional Genetics laboratory. In short, paired end reads were aligned to the human genome (GRCh37) using Burrows-Wheeler Aligner (BWA)-MEM version 0.7.15⁴⁷ and the variant calling was performed using Freebayes (sensitive settings; version 1.1.0; <https://github.com/ekg/freebayes>) using region of interest of the targeted genes. VEP87 and Gemini v0.20 were used for variant annotation and filtering. Variants were further annotated using Alamut-batch (version 1.9; <http://www.interactive-biosoftware.com/alamut-batch/>) and variants with ExAC frequency > 2% were filtered out. CNVs were called using a bioconductor package ExomeDepth (version 1.0.7; ⁴⁸) excluding sex chromosomes. Coverage depth was calculated using chanjo (version 2.3.2; <https://github.com/robinandeer/chanjo>).

eTable 1. List of laboratory investigations organized in context of routine clinical care for patients with suspected neuroinflammation. CSF=cerebrospinal fluid. ANA=antinuclear antibodies. ENA=extranuclear antibodies. ANCA=antineutrophil cytoplasmic antibodies. MOG=myelin oligodendrocyte antibodies.

Full blood count and blood film
Erythrocyte sedimentation rate
C-reactive protein
Urea creatinine and electrolytes
Liver function tests
CSF glucose and protein, microscopy and culture.
CSF/serum oligoclonal bands
CSF neopterin
Clotting screen
C3 and C4 levels, complement function
IgG/IgM/IgG
ANA/dsDNA/ENA
ANCA
MOG antibodies
Anti-aquaporin4 antibodies
Urine for albumin: creatinine ratio.
Thyroid function and thyroid antibodies
Plasma amino acids, lactate, ammonia
For patients with suspected vasculopathy plasma homocysteine and alpha galactosidase levels
Muscle biopsy for respiratory chain enzymes in case of suspected mitochondrial disease

eTable 2. Detailed list of genes included in Neuroinflammation panel (NIP).

<i>Gene</i>	<i>HGNC Symbol</i>	Gene Name	Disease Group	Chr	Transcript reference from HGNC
<i>ACTA2</i>	<i>ACTA2</i>	Actin alpha 2	Arteriopathies	10	NM_001613
<i>BMP2</i>	<i>BMP2</i>	Bone morphogenetic protein receptor type 2	Arteriopathies	2	NM_001204
<i>CBL</i>	<i>CBL</i>	Cbl proto-oncogene	Arteriopathies	11	NM_005188
<i>CBS</i>	<i>CBS</i>	Cystathionine-beta-synthase	Arteriopathies	21	NM_000071
<i>CECR1</i>	<i>CECR1</i>	Cat eye syndrome chromosome region 1/Adenosine deaminase 2	Arteriopathies	22	NM_001282225
<i>COL3A1</i>	<i>COL3A1</i>	Collagen type III alpha 1 chain	Arteriopathies	2	NM_000090
<i>COL4A1</i>	<i>COL4A1</i>	Collagen type IV alpha 1 chain	Arteriopathies	13	NM_001303110
<i>ELN</i>	<i>ELN</i>	Elastin	Arteriopathies	7	NM_000501
<i>FBN1</i>	<i>FBN1</i>	Fibrillin1	Arteriopathies	15	NM_000138
<i>FBN2</i>	<i>FBN2</i>	Fibrillin 2	Arteriopathies	5	NM_001999
<i>FOXE3</i>	<i>FOXE3</i>	Forkhead box E3	Arteriopathies	1	NM_012186
<i>FOXP3</i>	<i>FOXP3</i>	Forkhead box P3	Arteriopathies	X	NM_014009
<i>GUCY1A3</i>	<i>GUCY1A3</i>	Guanylate cyclase 1 soluble subunit alpha 1	Arteriopathies	4	NM_000856
<i>HTRA1</i>	<i>HTRA1</i>	HtrA serine peptidase-1 gene	Arteriopathies	10	NM_002775
<i>LOX</i>	<i>LOX</i>	Lysyl oxidase	Arteriopathies	5	NM_001178102
<i>MAT2A</i>	<i>MAT2A</i>	Methionine adenosyltransferase 2A	Arteriopathies	2	NM_005911
<i>MFAP5</i>	<i>MFAP5</i>	Microfibril associated protein 5	Arteriopathies	12	NM_003480
<i>MYH11</i>	<i>MYH11</i>	Myosin heavy chain 11	Arteriopathies	16	NM_001040113
<i>MYLK</i>	<i>MYLK</i>	Myosin light chain kinase	Arteriopathies	3	NM_053025
<i>NOTCH1</i>	<i>NOTCH1</i>	Notch 1	Arteriopathies	9	NM_017617
<i>NOTCH3</i>	<i>NOTCH3</i>	Notch 3	Arteriopathies	19	NM_000435
<i>PRKG1</i>	<i>PRKG1</i>	Protein kinase cGMP-dependent 1	Arteriopathies	10	NM_001098512
<i>RNF213</i>	<i>RNF213</i>	Ring finger protein 213	Arteriopathies	17	NM_020914
<i>SAMD3</i>	<i>SAMD3</i>	Sterile alpha motif domain containing 3	Arteriopathies	6	NM_152552
<i>SKI</i>	<i>SKI</i>	SKI proto-oncogene	Arteriopathies	1	NM_003036

<i>SLC2A10</i>	<i>SLC2A10</i>	Solute carrier family 2 member 10	Arteriopathies	20	NM_030777
<i>SMAD2</i>	<i>SMAD2</i>	SMAD family member 2	Arteriopathies	18	NM_005901
<i>SMAD3</i>	<i>SMAD3</i>	SMAD family member 3	Arteriopathies	15	NM_005902
<i>SMAD4</i>	<i>SMAD4</i>	SMAD family member 4	Arteriopathies	18	NM_005359
<i>TGFB2</i>	<i>TGFB2</i>	Transforming growth factor beta 2	Arteriopathies	1	NM_003238
<i>TGFB3</i>	<i>TGFB3</i>	Transforming growth factor beta 3	Arteriopathies	14	NM_003239
<i>TGFBI</i>	<i>TGFBI</i>	Transforming growth factor beta induced	Arteriopathies	5	NM_000358
<i>TGFBR1</i>	<i>TGFBR1</i>	Transforming growth factor beta receptor 1	Arteriopathies	5	NM_000358
<i>TGFBR2</i>	<i>TGFBR2</i>	transforming growth factor beta receptor 2	Arteriopathies	3	NM_001024847
<i>USB1</i>	<i>USB1</i>	U6 snRNA biogenesis phosphodiesterase 1	Arteriopathies	16	NM_024598
<i>YYIAP1</i>	-	YY1 associated protein 1	Arteriopathies	1	NM_139118
<i>COPA</i>	<i>COPA</i>	Coatomer protein complex subunit alpha	Autoinflammatory	1	NM_004371
<i>CTLA4</i>	<i>CTLA4</i>	Cytotoxic T-lymphocyte associated protein 4	Autoinflammatory	2	NM_005214
<i>IL1RN</i>	<i>IL1RN</i>	Interleukin 1 receptor antagonist	Autoinflammatory	2	NM_173841
<i>LPIN2</i>	<i>LPIN2</i>	LPIN2	Autoinflammatory	18	NM_014646
<i>MEFV</i>	<i>MEFV</i>	Mediterranean Fever	Autoinflammatory	16	NM_000243
<i>MVK</i>	<i>MVK</i>	Mevalonate Kinase	Autoinflammatory	16	NM_000243
<i>NLRP12</i>	<i>NLRP12</i>	NLR family pyrin domain containing 12	Autoinflammatory	19	NM_144687
<i>NLRP3</i>	<i>NLRP3</i>	NLR family pyrin domain containing 3	Autoinflammatory	1	NM_004895
<i>NOD2</i>	<i>NOD2</i>	Nucleotide binding oligomerization domain containing 2	Autoinflammatory	16	NM_022162
<i>OTULIN</i>	<i>OTULIN</i>	OTU deubiquitinase with linear linkage specificity	Autoinflammatory	5	NM_138348
<i>PLCG2</i>	<i>PLCG2</i>	Phospholipase C gamma 2	Autoinflammatory	16	NM_002661
<i>PLOD1</i>	<i>PLOD1</i>	Procollagen-lysine,2-oxoglutarate 5-dioxygenase 1	Autoinflammatory	1	NM_000302

<i>PSMA3</i>	<i>PSMA3</i>	Proteasome subunit alpha 3	Autoinflammatory	14	NM_002788
<i>PSTPIP1</i>	<i>PSTPIP1</i>	Proline-serine-threonine phosphatase interacting protein 1	Autoinflammatory	15	NM_003978
<i>PYCARD</i>	<i>PYCARD</i>	PYD and CARD domain containing	Autoinflammatory	16	NM_013258
<i>RBCK1</i>	<i>RBCK1</i>	RANBP2-type and C3HC4-type zinc finger containing 1	Autoinflammatory	20	NM_031229
<i>TNFAIP3</i>	<i>TNFAIP3</i>	TNF alpha induced protein 3	Autoinflammatory	6	NM_001270507
<i>TNFRSF1A</i>	<i>TNFRSF1A</i>	TNF receptor superfamily member 1A	Autoinflammatory	12	NM_001065
<i>TRAP1</i>	<i>TRAP2</i>	TNF receptor associated protein 1	Autoinflammatory	16	NM_016292
<i>TRIM28</i>	<i>TRIM28</i>	tripartite motif containing 28	Autoinflammatory	19	NM_005762
<i>TRNT1</i>	<i>TRNT1</i>	tRNA nucleotidyl transferase 1	Autoinflammatory	3	NM_001302946
<i>WDR1</i>	<i>WDR1</i>	WD repeat domain 1	Autoinflammatory	4	NM_005112
<i>CIQA</i>	<i>CIQA</i>	Complement component 1, q subcomponent, A chain	Complement disorders	1	NM_015991
<i>CIQB</i>	<i>CIQB</i>	Complement component 1, q subcomponent, B chain	Complement disorders	1	NM_000491
<i>CIQC</i>	<i>CIQC</i>	Complement component 1, q subcomponent, C chain	Complement disorders	1	NM_172369
<i>C1R</i>	<i>C1R</i>	Complement component 1r	Complement disorders	12	NM_001733
<i>C2</i>	<i>C2</i>	Complement component 2	Complement disorders	6	NM_000063
<i>C3</i>	<i>C3</i>	Complement component 3	Complement disorders	19	NM_000064
<i>C5</i>	<i>C5</i>	Complement component 5	Complement disorders	9	NM_001735
<i>C6</i>	<i>C6</i>	Complement component 6	Complement disorders	5	NM_000065
<i>C7</i>	<i>C7</i>	Complement component 7	Complement disorders	5	NM_000587
<i>C8A</i>	<i>C8A</i>	Complement component 8 alpha	Complement disorders	1	NM_000562
<i>C8B</i>	<i>C8B</i>	Complement component 8 beta	Complement disorders	1	NM_000066
<i>CFH</i>	<i>CFH</i>	Complement factor H	Complement disorders	1	NM_000186

<i>CFHR5</i>	<i>CFHR5</i>	Complement factor H-related protein 5	Complement disorders	1	NM_030787
<i>CFI</i>	<i>CFI</i>	Complement factor 1	Complement disorders	4	NM_000204
<i>CTPS1</i>	<i>CTPS1</i>	CTP synthase 1	Complement disorders	1	NM_001905
<i>MASP2</i>	<i>MASP2</i>	Mannan binding lectin serine peptidase 2	Complement disorders	1	NM_006610
<i>RANBP2</i>	<i>RANBP2</i>	RAN binding protein 2	Encephalomyelitis	2	NM_006267
<i>NLRC4</i>	<i>NLRC4</i>	NLR family CARD domain containing 4	Haemophagocytic lymphosticytosis	2	NM_021209
<i>PRF1</i>	<i>PRF1</i>	Perforin 1	Haemophagocytic lymphosticytosis	10	NM_005041
<i>SH2D1A</i>	<i>SH2D1A</i>	SH2 domain containing 1A	Haemophagocytic lymphosticytosis	X	NM_002351
<i>SLC29A3</i>	<i>SLC29A3</i>	Solute carrier family 29 member 3	Haemophagocytic lymphosticytosis	10	NM_018344
<i>STX11</i>	<i>STX11</i>	Syntaxin 11	Haemophagocytic lymphosticytosis	6	NM_003764
<i>STXBP2</i>	<i>STXBP2</i>	Syntaxin binding protein 2	Haemophagocytic lymphosticytosis	19	NM_006949
<i>UNC13D</i>	<i>UNC13D</i>	Unc-13 homolog D	Haemophagocytic lymphosticytosis	17	NM_199242
<i>XIAP</i>	<i>XIAP</i>	X-linked inhibitor of apoptosis	Haemophagocytic lymphosticytosis	x	NM_001167
<i>CLEC16A</i>	<i>CLEC16A</i>	C-type lectin domain containing 16A	Immunodeficiency	16	NM_015226
<i>FAS</i>	<i>FAS</i>	Fas cell surface death receptor	Immunodeficiency	10	NM_000043
<i>GATA2</i>	<i>GATA2</i>	GATA binding protein 2	Immunodeficiency	3	NM_032638
<i>IRF5</i>	<i>IRF5</i>	Interferon regulatory factor 5	Immunodeficiency	7	NM_001098627
<i>IRF8</i>	<i>IRF8</i>	Interferon regulatory factor 8	Immunodeficiency	16	NM_002163
<i>ITPR3</i>	<i>ITPR3</i>	Inositol 1,4,5-trisphosphate receptor type 3	Immunodeficiency	6	NM_002224
<i>MYO5A</i>	<i>MYO5A</i>	Myosin VA	Immunodeficiency	15	NM_000259
<i>PTPN22</i>	<i>PTPN22</i>	Protein tyrosine phosphatase, non-receptor type 22	Immunodeficiency	1	NM_015967
<i>RHOD</i>	<i>RHOD</i>	Ras homolog family member D	Immunodeficiency	11	NM_014578
<i>STAT3</i>	<i>STAT3</i>	Signal transducer and activator of transcription 3	Immunodeficiency	17	NM_139276
<i>STAT4</i>	<i>STAT4</i>	Signal transducer and activator of transcription 4	Immunodeficiency	2	NM_003151

<i>TBK1</i>	<i>TBK1</i>	TANK binding kinase 1	Immunodeficiency	12	NM_013254
<i>ACP5</i>	<i>ACP5</i>	Acid phosphatase-5/tartrate-resistant phosphatase	Interferonopathies	19	NM_001111034
<i>ADAR</i>	<i>ADAR1</i>	Adenosine deaminase, RNA specific	Interferonopathies	1	NM_001111
<i>DDX58</i>	<i>DDX58</i>	DEx/D/H-box helicase 58	Interferonopathies	9	NM_014314
<i>DNASE1</i>	<i>DNASE1</i>	Deoxyribonuclease 1	Interferonopathies	16	NM_001351825
<i>DNASE1L3</i>	<i>DNASE1L3</i>	Deoxyribonuclease I-like 3	Interferonopathies	3	NM_004944
<i>DNASE2</i>	<i>DNaseII</i>	Deoxyribonuclease 2, lysosomal	Interferonopathies	19	NM_001375
<i>IFIH1</i>	<i>IFIH1</i>	Interferon induced with helicase C domain 1	Interferonopathies	2	NM_022168
<i>ISG15</i>	<i>ISG15</i>	ISG15 ubiquitin-like modifier	Interferonopathies	1	NM_005101
<i>NDUFS1</i>	<i>NDUFS1</i>	NADH:ubiquinone oxidoreductase core subunit S1	White matter metabolic disease	2	NM_005006
<i>NDUFS2</i>	<i>NDUFS2</i>	NADH:ubiquinone oxidoreductase core subunit S2	White matter metabolic disease	1	NM_004550
<i>NDUFS3</i>	<i>NDUFS3</i>	NADH:ubiquinone oxidoreductase core subunit S3	White matter metabolic disease	11	NM_004551
<i>NDUFS4</i>	<i>NDUFS4</i>	NADH:ubiquinone oxidoreductase subunit S4	White matter metabolic disease	5	NM_002495
<i>NDUFS5</i>	<i>NDUFS5</i>	NADH:ubiquinone oxidoreductase subunit S5	White matter metabolic disease	1	NM_004552
<i>NDUFS6</i>	<i>NDUFS6</i>	NADH:ubiquinone oxidoreductase subunit S6	White matter metabolic disease	5	NM_004553
<i>NDUFS7</i>	<i>NDUFS7</i>	NADH:ubiquinone oxidoreductase subunit S6	White matter metabolic disease	5	NM_004553
<i>NDUFS8</i>	<i>NDUFS8</i>	NADH:ubiquinone oxidoreductase core subunit S8	White matter metabolic disease	11	NM_002496
<i>POMP</i>	<i>POMP</i>	Proteasome maturation protein	Interferonopathies	13	NM_015932
<i>PRKCD</i>	<i>PRKCD</i>	Protein kinase C delta	Interferonopathies	3	NM_001316327
<i>PSMB3</i>	<i>PSMB3</i>	Proteasome subunit beta 3	Interferonopathies	17	NM_002795
<i>PSMB4</i>	<i>PSMB4</i>	Proteasome subunit beta 4	Interferonopathies	1	NM_002796
<i>PSMB8</i>	<i>PSMB8</i>	Proteasome subunit beta 8	Interferonopathies	6	NM_148919

<i>PSMB9</i>	<i>PSMB9</i>	Proteasome subunit beta 9	Interferonopathies	6	NM_002800
<i>RAB27A</i>	<i>RAB27A</i>	RAB27A, member RAS oncogene family	Haemophagocytic lymphohistiocytosis	15	NM_004580
<i>RNASEH2A</i>	<i>RNASEH2A</i>	Ribonuclease H2 subunit A	Interferonopathies	19	NM_006397
<i>RNASEH2B</i>	<i>RNASEH2B</i>	Ribonuclease H2 subunit B	Interferonopathies	13	NM_024570
<i>RNASEH2C</i>	<i>RNASEH2C</i>	Ribonuclease H2 subunit C	Interferonopathies	11	NM_032193
<i>SAMHD1</i>	<i>SAMHD1</i>	SAM and HD domain containing deoxynucleoside triphosphate triphosphohydrolase 1	Interferonopathies	20	NM_015474
<i>SKIV2L</i>	<i>SKIV2L</i>	Ski2 like RNA helicase	Immunodeficiency	6	NM_006929
<i>STAT2</i>	<i>STAT2</i>	Signal transducer and activator of transcription 2	Immunodeficiency	12	NM_005419
<i>TMEM173</i>	<i>TMEM173</i>	Transmembrane protein 173	Interferonopathies	5	NM_198282
<i>TREX1</i>	<i>TREX1</i>	three prime repair exonuclease 1	Interferonopathies	3	NM_016381
<i>USP18</i>	<i>USP18</i>	Ubiquitin specific peptidase 18	Interferonopathies	22	NM_017414
<i>EGR2</i>	<i>EGR2</i>	Early growth response 2	Neuropathies	10	NM_000399
<i>LMNA</i>	<i>LMNA</i>	Lamin A/C	Neuropathies	1	NM_170707
<i>LMNB1</i>	<i>LMNB1</i>	Lamin B1	Neuropathies	5	NM_005573
<i>GJB1</i>	<i>GJB1</i>	Gap junction protein beta 1	Neuropathies	X	NM_000166
<i>MFN2</i>	<i>MFN2</i>	Mitofusin 2	Neuropathies	1	NM_014874
<i>MPZ</i>	<i>MPZ</i>	Myelin protein zero	Neuropathies	1	NM_000530
<i>NEFL</i>	<i>NEFL</i>	Neurofilament light	Neuropathies	8	NM_006158
<i>NF1</i>	<i>NF1</i>	Neurofibromin 1	Neuropathies	17	NM_000267
<i>PMP22</i>	<i>PMP22</i>	Peripheral myelin protein 22	Neuropathies	17	NM_000304
<i>PRX</i>	<i>PRX</i>	Periaxin	Neuropathies	19	NM_020956
<i>TSC1</i>	<i>TSC1</i>	TSC complex subunit 1	Neuropathies	9	NM_000368
<i>TSC2</i>	<i>TSC2</i>	TSC complex subunit 2	Neuropathies	16	NM_000548
<i>TTC37</i>	<i>TTC37</i>	Tetratricopeptide repeat domain 37	Neuropathies	5	NM_014639
<i>LYST</i>	<i>LYST</i>	Lysosomal trafficking regulator	White matter and metabolic diseases	1	NM_000081
<i>ATP7B</i>	<i>ATP7B</i>	ATPase copper transporting beta	White matter and metabolic diseases	13	NM_000053

<i>CORO1A</i>	<i>CORO1A</i>	Coronin 1A	White matter and metabolic diseases	16	NM_007074
<i>CPT2</i>	<i>CPT2</i>	Carnitine palmitoyltransferase 2	White matter and metabolic diseases	1	NM_000098
<i>FOLR1</i>	<i>FOLR1</i>	Folate receptor 1	White matter and metabolic diseases	11	NM_016725
<i>HMBS</i>	<i>HMBS</i>	Hydroxymethylbilane synthase	White matter and metabolic diseases	11	NM_000190
<i>PHYH</i>	<i>PHYH</i>	Phytanoyl-CoA 2-hydroxylase	White matter and metabolic diseases	10	NM_001037537
<i>ARX</i>	<i>ARX</i>	Aristaless related homeobox	White matter and metabolic diseases	X	NM_139058
<i>ISCA2</i>	<i>ISCA2</i>	Iron-sulfur cluster assembly 2	White matter and metabolic diseases	14	NM_194279
<i>AARS2</i>	<i>AARS2</i>	Alanyl-tRNA synthetase 2, mitochondrial	White matter and metabolic diseases	6	NM_020745
<i>ABCD1</i>	<i>ABCD1</i>	ATP binding cassette subfamily D member 1	White matter and metabolic diseases	X	NM_000033
<i>ACOX1</i>	<i>ACOX1</i>	Acyl-CoA oxidase 1	White matter and metabolic diseases	17	NM_001185039
<i>ADCK3</i>	<i>ADCK3</i>	Coenzyme Q8A	White matter and metabolic diseases	1	NM_020247
<i>AIFM1</i>	<i>AIFM1</i>	Apoptosis inducing factor mitochondria associated 1	White matter and metabolic diseases	X	NM_001130846
<i>AIMP1</i>	<i>AIMP1</i>	Aminoacyl tRNA synthetase complex interacting multifunctional protein 1	White matter and metabolic diseases	4	NM_004757
<i>ALDH3A2</i>	<i>ALDH3A2</i>	Aldehyde dehydrogenase 3 family member A2	White matter and metabolic diseases	17	NM_000382
<i>ARSA</i>	<i>ARSA</i>	Arylsulfatase A	White matter and metabolic diseases	22	NM_000487
<i>ASPA</i>	<i>ASPA</i>	Aspartoacylase	White matter and metabolic diseases	17	NM_000049
<i>ATPAF2</i>	<i>ATPAF2</i>	ATP synthase mitochondrial F1 complex assembly factor 2	White matter and metabolic diseases	17	NM_145691
<i>BCS1L</i>	<i>BCS1L</i>	BCS1 homolog, ubiquinol-cytochrome c reductase complex chaperone	White matter and metabolic diseases	2	NM_004328
<i>BOLA3</i>	<i>BOLA3</i>	BolA family member 3	White matter and metabolic diseases	2	NM_212552
<i>BTD</i>	<i>BTD</i>	Biotinidase	White matter and metabolic diseases	3	NM_000060

<i>CLCN2</i>	<i>CLCN2</i>	Chloride voltage-gated channel 2	White matter and metabolic diseases	3	NM_001171087
<i>COQ2</i>	<i>COQ2</i>	Coenzyme Q2, polyprenyltransferase	White matter and metabolic diseases	4	NM_015697
<i>COQ9</i>	<i>COQ9</i>	Coenzyme Q9	White matter and metabolic diseases	16	NM_020312
<i>COX10</i>	<i>COX10</i>	Cytochrome c oxidase assembly factor heme A:farnesyltransferase	White matter and metabolic diseases	17	NM_001303
<i>COX15</i>	<i>COX15</i>	Cytochrome c oxidase assembly homolog COX15	White matter and metabolic diseases	10	NM_078470
<i>CSF1R</i>	<i>CSF1R</i>	Colony stimulating factor 1 receptor	White matter and metabolic diseases	5	NM_005211
<i>CST3</i>	<i>CST3</i>	Cystatin C	White matter and metabolic diseases	20	NM_000099
<i>CTC1</i>	<i>CTC1</i>	CST telomere replication complex component 1	White matter and metabolic diseases	17	NM_025099
<i>CYP27A1</i>	<i>CYP27A1</i>	Cytochrome P450 family 27 subfamily A member 1	White matter and metabolic diseases	2	NM_000784
<i>DARS</i>	<i>DARS</i>	Aspartyl-tRNA synthetase	White matter and metabolic diseases	2	NM_001349
<i>DARS2</i>	<i>DARS2</i>	Aspartyl-tRNA synthetase 2, mitochondrial	White matter and metabolic diseases	1	NM_018122
<i>DGUOK</i>	<i>DGUOK</i>	Deoxyguanosine kinase	White matter and metabolic diseases	2	NM_001318859
<i>EARS2</i>	<i>EARS2</i>	Glutamyl-tRNA synthetase 2, mitochondrial	White matter and metabolic diseases	16	NM_133451
<i>EIF2B1</i>	<i>EIF2B1</i>	Eukaryotic translation initiation factor 2B subunit alpha	White matter and metabolic diseases	12	NM_001414
<i>EIF2B2</i>	<i>EIF2B2</i>	Eukaryotic translation initiation factor 2B subunit beta	White matter and metabolic diseases	14	NM_014239
<i>EIF2B3</i>	<i>EIF2B3</i>	Eukaryotic translation initiation factor 2B subunit gamma	White matter and metabolic diseases	1	NM_020365
<i>EIF2B4</i>	<i>EIF2B4</i>	Eukaryotic translation initiation factor 2B subunit delta	White matter and metabolic diseases	2	NM_001034116
<i>EIF2B5</i>	<i>EIF2B5</i>	Eukaryotic translation initiation factor 2B subunit epsilon	White matter and metabolic diseases	3	NM_003907

<i>ERCC2</i>	<i>ERCC2</i>	ERCC excision repair 2, TFIIH core complex helicase subunit	White matter and metabolic diseases	19	NM_000400
<i>ERCC3</i>	<i>ERCC3</i>	ERCC excision repair 3, TFIIH core complex helicase subunit	White matter and metabolic diseases	2	NM_000122
<i>ERCC6</i>	<i>ERCC6</i>	ERCC excision repair 6, chromatin remodeling factor	White matter and metabolic diseases	10	NM_000124
<i>ERCC8</i>	<i>ERCC8</i>	ERCC excision repair 8, CSA ubiquitin ligase complex subunit	White matter and metabolic diseases	5	NM_000082
<i>ETFDH</i>	<i>ETFDH</i>	Electron transfer flavoprotein dehydrogenase	White matter and metabolic diseases	4	NM_001281737
<i>EXOSC8</i>	<i>EXOSC8</i>	Exosome component 8	White matter and metabolic diseases	13	NM_181503
<i>FAM126A</i>	<i>FAM126A</i>	Family with sequence similarity 126 member A	White matter and metabolic diseases	7	NM_032581
<i>FUCA1</i>	<i>FUCA1</i>	Alpha-L-fucosidase 1	White matter and metabolic diseases	1	NM_000147
<i>FXN</i>	<i>FXN</i>	Frataxin	White matter and metabolic diseases	9	NM_000144
<i>GALC</i>	<i>GALC</i>	Galactosylceramidase	White matter and metabolic diseases	14	NM_000153
<i>GBE1</i>	<i>GBE1</i>	1,4-alpha-glucan branching enzyme 1	White matter and metabolic diseases	3	NM_000158
<i>GFAP</i>	<i>GFAP</i>	Glial fibrillary acidic protein	White matter and metabolic diseases	17	NM_002055
<i>GFM1</i>	<i>GFM1</i>	Elongation factor mitochondrial G1	White matter and metabolic diseases	3	NM_024996
<i>GJC2</i>	<i>GJC2</i>	Gap junction protein gamma 2	White matter and metabolic diseases	1	NM_020435
<i>GLA</i>	<i>GLA</i>	Galactosidase alpha	White matter and metabolic diseases	X	NM_000169
<i>GTF2H5</i>	<i>GTF2H5</i>	General transcription factor IIH subunit 5	White matter and metabolic diseases	6	NM_207118
<i>HEPACAM</i>	<i>HEPACAM</i>	Hepatic and glial cell adhesion molecule	White matter and metabolic diseases	11	NM_152722
<i>HFE</i>	<i>HFE</i>	Homeostatic iron regulator	White matter and metabolic diseases	6	NM_000410
<i>HSD17B4</i>	<i>HSD17B4</i>	Hydroxysteroid 17-beta dehydrogenase 4	White matter and metabolic diseases	5	NM_000414
<i>IBA57</i>	<i>IBA57</i>	IBA57, iron-sulfur cluster assembly	White matter and metabolic diseases	1	NM_001010867
<i>LONP1</i>	<i>LONP1</i>	Lon peptidase 1, mitochondrial	White matter and metabolic diseases	16	NM_004793
<i>MLC1</i>	<i>MLC1</i>	Megalencephalic leukoencephalopathy	White matter and metabolic diseases	22	NM_015166

		with subcortical cysts 1			
<i>MPLKIP</i>	<i>MPLKIP</i>	M-phase specific PLK1 interacting protein	White matter and metabolic diseases	7	NM_138701
<i>MRPS16</i>	<i>MRPS16</i>	Mitochondrial ribosomal protein S16	White matter and metabolic diseases	10	NM_016065
<i>NDUFAF1</i>	<i>NDUFAF1</i>	NADH:ubiquinone oxidoreductase complex assembly factor 1	White matter and metabolic diseases	15	NM_016013
<i>NDUFV1</i>	<i>NDUFV1</i>	NADH:ubiquinone oxidoreductase core subunit V1	White matter and metabolic diseases	11	NM_007103
<i>NUBPL</i>	<i>NUBPL</i>	Nucleotide binding protein like	White matter and metabolic diseases	14	NM_025152
<i>PARN</i>	<i>PARN</i>	Poly(A)-specific ribonuclease	White matter and metabolic diseases	16	NM_002582
<i>PDHA1</i>	<i>PDHA1</i>	Pyruvate dehydrogenase E1 alpha 1 subunit	White matter and metabolic diseases	x	NM_000284
<i>PEX1</i>	<i>PEX1</i>	Peroxisomal biogenesis factor 1	White matter and metabolic diseases	7	NM_000466
<i>PEX10</i>	<i>PEX10</i>	Peroxisomal biogenesis factor 10	White matter and metabolic diseases	1	NM_153818
<i>PEX11A</i>	<i>PEX11A</i>	Peroxisomal biogenesis factor 11 alpha	White matter and metabolic diseases	15	NM_003847
<i>PEX11B</i>	<i>PEX11B</i>	Peroxisomal biogenesis factor 11 beta	White matter and metabolic diseases	1	NM_003846
<i>PEX12</i>	<i>PEX12</i>	Peroxisomal biogenesis factor 12	White matter and metabolic diseases	17	NM_000286
<i>PEX13</i>	<i>PEX13</i>	Peroxisomal biogenesis factor 13	White matter and metabolic diseases	2	NM_002618
<i>PEX14</i>	<i>PEX14</i>	Peroxisomal biogenesis factor 14	White matter and metabolic diseases	1	NM_004565
<i>PEX16</i>	<i>PEX16</i>	Peroxisomal biogenesis factor 16	White matter and metabolic diseases	11	NM_057174
<i>PEX2</i>	<i>PEX2</i>	Peroxisomal biogenesis factor 2	White matter and metabolic diseases	8	NM_000318
<i>PEX3</i>	<i>PEX3</i>	Peroxisomal biogenesis factor 3	White matter and metabolic diseases	6	NM_003630
<i>PEX26</i>	<i>PEX26</i>	Peroxisomal biogenesis factor 26	White matter and metabolic diseases	22	NM_017929
<i>PEX5</i>	<i>PEX5</i>	Peroxisomal biogenesis factor 5	White matter and metabolic diseases	12	NM_000319
<i>PEX6</i>	<i>PEX6</i>	Peroxisomal biogenesis factor 6	White matter and metabolic diseases	6	NM_000287
<i>PEX7</i>	<i>PEX7</i>	Peroxisomal biogenesis factor 7	White matter and metabolic diseases	6	NM_000288
<i>PGM3</i>	<i>PGM3</i>	Phosphoglucomutase 3	White matter and metabolic diseases	6	NM_015599

<i>PLP1</i>	<i>PLP1</i>	Proteolipid protein 1	White matter and metabolic diseases	x	NM_000533
<i>POLG</i>	<i>POLG</i>	DNA polymerase gamma, catalytic subunit	White matter and metabolic diseases	15	NM_002693
<i>POLG2</i>	<i>POLG2</i>	DNA polymerase gamma 2, accessory subunit	White matter and metabolic diseases	17	NM_007215
<i>POLR1C</i>	<i>POLR1C</i>	POLR1C	White matter and metabolic diseases	6	NM_004875
<i>POLR3A</i>	<i>POLR3A</i>	RNA polymerase III subunit A	White matter and metabolic diseases	10	NM_007055
<i>POLR3B</i>	<i>POLR3B</i>	RNA polymerase III subunit B	White matter and metabolic diseases	12	NM_018082
<i>PSAP</i>	<i>PSAP</i>	Prosaposin	White matter and metabolic diseases	10	NM_002778
<i>PYCR2</i>	<i>PYCR2</i>	Pyrroline-5-carboxylate reductase 2	White matter and metabolic diseases	1	NM_013328
<i>RARS</i>	<i>RARS</i>	Arginyl-tRNA synthetase	White matter and metabolic diseases	5	NM_002887
<i>RASGRP1</i>	<i>RASGRP1</i>	RAS guanyl releasing protein 1	White matter and metabolic diseases	15	NM_005739
<i>RNASET2</i>	<i>RNASET2</i>	Ribonuclease T2	White matter and metabolic diseases	6	NM_003730
<i>RRM2B</i>	<i>RRM2B</i>	Ribonucleotide reductase regulatory TP53 inducible subunit M2B	White matter and metabolic diseases	8	NM_001172477
<i>SCN9A</i>	<i>SCN9A</i>	Sodium voltage-gated channel alpha subunit 9	White matter and metabolic diseases	2	NM_002977
<i>SCO1</i>	<i>SCO1</i>	SCO1, cytochrome c oxidase assembly protein	White matter and metabolic diseases	17	NM_004589
<i>SCO2</i>	<i>SCO2</i>	SCO2, cytochrome c oxidase assembly protein	White matter and metabolic diseases	22	NM_005138
<i>SCP2</i>	<i>SCP2</i>	Sterol carrier protein 2	White matter and metabolic diseases	1	NM_002979
<i>SDHAF1</i>	<i>SDHAF1</i>	succinate dehydrogenase complex assembly factor 1	White matter and metabolic diseases	19	NM_001042631
<i>SDHB</i>	<i>SDHB</i>	succinate dehydrogenase complex iron sulfur subunit B	White matter and metabolic diseases	1	NM_003000
<i>SLC16A2</i>	<i>SLC16A2</i>	Solute carrier family 16 member 2	White matter and metabolic diseases	x	NM_006517
<i>SLC17A5</i>	<i>SLC17A5</i>	Solute carrier family 17 member 5	White matter and metabolic diseases	6	NM_012434
<i>SLCIA4</i>	<i>SLCIA4</i>	Solute carrier family 1 member 4	White matter and metabolic diseases	2	NM_003038

<i>SLC25A12</i>	<i>SLC25A12</i>	Solute carrier family 25 member 12	White matter and metabolic diseases	2	NM_003705
<i>SOX10</i>	<i>SOX10</i>	SRY-box 10	White matter and metabolic diseases	22	NM_006941
<i>SPTAN1</i>	<i>SPTAN1</i>	Spectrin alpha, non-erythrocytic 1	White matter and metabolic diseases	9	NM_003127
<i>SUCLA2</i>	<i>SUCLA2</i>	Succinate-CoA ligase ADP-forming beta subunit	White matter and metabolic diseases	13	NM_003850
<i>SUMF1</i>	<i>SUMF1</i>	Sulfatase modifying factor 1	White matter and metabolic diseases	3	NM_182760
<i>SURF1</i>	<i>SURF1</i>	SURF1, cytochrome c oxidase assembly factor	White matter and metabolic diseases	9	NM_003172
<i>TACO1</i>	<i>TACO1</i>	Translational activator of cytochrome c oxidase I	White matter and metabolic diseases	17	NM_016360
<i>TUBB4A</i>	<i>TUBB4A</i>	Tubulin beta 4A class IVa	White matter and metabolic diseases	19	NM_006087
<i>TUFM</i>	<i>TUFM</i>	Tu translation elongation factor, mitochondrial	White matter and metabolic diseases	16	NM_003321
<i>TYMP</i>	<i>TYMP</i>	Thymidine phosphorylase	White matter and metabolic diseases	22	NM_001953
<i>NFU1</i>	<i>NFU1</i>	NFU1 iron-sulfur cluster scaffold	White matter and metabolic diseases	2	NM_015700
<i>SNORD118</i>	<i>SNORD118</i>	SMALL NUCLEOLAR RNA, C/D BOX, 118	White matter and metabolic diseases	17	NR_033294

eTable 3. SureDesign description of probes for NIP.

MiSeq sequencing runs	NIP Design ID	NIP gene list version	Description	Number of genes	Number of regions	Number of probes	Probe size (Kbp)
Run 1	3065351	NIP 1	NIP1 genes	257	3448	23940	877.433
Run 2	3102591	NIP 1.1	NIP1 modified with more baits added to 54 regions in 28 genes and 1 region added	257	3450	24547	895.455
Run 3		NIP 1.1					
Run 4		NIP 1.1					

eTable 4. Regions below the depth of coverage threshold of 30X.

C5= complement component 5; *CFH*= complement factor H; *CFI*= complement factor 1; *CORO1A*= coronin 1A; *NF1*= neurofibromin 1; *POMP*= proteasome maturation protein; *PTPN22*= protein tyrosine phosphatase, non-receptor type 22; *RANBP2*= RANBP2-type and C3HC4-type zinc finger containing 1; *SMAD4*= SMAD family member 4; *STAT4*= signal transducer and activator of transcription 4; *TBK1*= TANK binding kinase 1; *USP18*= ubiquitin specific peptidase 18.

Gene	Chromosome	Start	Stop	Mean reads
		Coordinates	Coordinates	
<i>C5</i>	chr9	1.24E+08	1.24E+08	20.2813
<i>CFH</i>	chr1	1.97E+08	1.97E+08	28.1719
<i>CFI</i>	chr4	1.11E+08	1.11E+08	20.9531
<i>CORO1A</i>	chr16	30200112	30200352	2.53125
<i>NF1</i>	chr17	29548982	29549162	15.7031
<i>NF1</i>	chr17	29548796	29548976	26.3906
<i>POMP</i>	chr13	29238585	29238765	8.17188
<i>PTPN22</i>	chr1	1.14E+08	1.14E+08	1.03125
<i>RANBP2</i>	chr2	1.09E+08	1.09E+08	13.7188
<i>RANBP2</i>	chr2	1.09E+08	1.09E+08	14.5625
<i>RANBP2</i>	chr2	1.09E+08	1.09E+08	20.7031
<i>RANBP2</i>	chr2	1.09E+08	1.09E+08	21.9063
<i>RANBP2</i>	chr2	1.09E+08	1.09E+08	23.6719

<i>RANBP2</i>	chr2	1.09E+08	1.09E+08	26.9375
<i>RANBP2</i>	chr2	1.09E+08	1.09E+08	27.8906
<i>RANBP2</i>	chr2	1.09E+08	1.09E+08	28.6094
<i>SMAD4</i>	chr18	48578898	48579018	0.73438
<i>STAT4</i>	chr2	1.92E+08	1.92E+08	25.8281
<i>TBK1</i>	chr12	64890076	64890256	3.3125
<i>USP18</i>	chr22	18649941	18650181	6.0625

eTable 5. List of regions with more baits added to improve coverage.

Gene	Chromosome	Start Coordinates	Stop Coordinates
<i>C5</i>	chr9	123744892	123745132
<i>C5</i>	chr9	123800134	123800314
<i>CECR1</i>	chr22	17700000	17700800
<i>CECR1</i>	chr22	17702200	17702900
<i>CFH</i>	chr1	196716221	196716461
<i>CFI</i>	chr4	110678838	110679193
<i>CORO1A</i>	chr16	30200112	30200352
<i>DARS</i>	chr2	136670005	136670185
<i>DARS2</i>	chr1	173814307	173814487
<i>ERCC8</i>	chr5	60200569	60200749
<i>FAS</i>	chr10	90771600	90772000
<i>FBN2</i>	chr5	127642770	127642950
<i>GUCY1A3</i>	chr4	156625024	156625204
<i>HSD17B4</i>	chr5	118807272	118807452
<i>LYST</i>	chr1	235875330	235875570
<i>LYST</i>	chr1	235963562	235963742
<i>MYO5A</i>	chr15	52640928	52641108
<i>MYO5A</i>	chr15	52688463	52688643
<i>NF1</i>	chr17	29541415	29541655
<i>NF1</i>	chr17	29548796	29548976
<i>NF1</i>	chr17	29548982	29549162
<i>NF1</i>	chr17	29579896	29580076
<i>PARN</i>	chr16	14678536	14678716
<i>PEX1</i>	chr7	92116722	92116902
<i>PEX1</i>	chr7	92140189	92140429

<i>Pomp</i>	chr13	29238585	29238765
<i>RANBP2</i>	chr2	109345531	109345711
<i>RANBP2</i>	chr2	109347165	109347405
<i>RANBP2</i>	chr2	109347733	109347973
<i>RANBP2</i>	chr2	109363120	109363300
<i>RANBP2</i>	chr2	109365360	109365600
<i>RANBP2</i>	chr2	109367690	109367930
<i>RANBP2</i>	chr2	109368268	109368508
<i>RANBP2</i>	chr2	109369827	109370067
<i>RANBP2</i>	chr2	109370233	109370473
<i>RANBP2</i>	chr2	109371583	109371763
<i>RANBP2</i>	chr2	109378513	109378693
<i>SH2D1A</i>	chrX	123505130	123505310
<i>SLC17A5</i>	chr6	74345043	74345283
<i>SMAD4</i>	chr18	48578898	48579018
<i>STAT4</i>	chr2	191923375	191923555
<i>TBK1</i>	chr12	64853918	64854158
<i>TBK1</i>	chr12	64883769	64883949
<i>TBK1</i>	chr12	64890076	64890256
<i>TRNT1</i>	chr3	3186210	3186450
<i>TTC37</i>	chr5	94842586	94842766
<i>USP18</i>	chr22	18649971	18650151
<i>USP18</i>	chr22	18650609	18650849
<i>USP18</i>	chr22	18652568	18652748
<i>USP18</i>	chr22	18653483	18653723
<i>USP18</i>	chr22	18659471	18659651
<i>XIAP</i>	chrX	123025014	123025194

eTable 6. Clinical features and class 4 and 5 genetic variants identified on Neuroinflammation gene panel (NIP) in patients with suspected genetic neuroinflammatory disorders and unknown molecular diagnoses. MRI=magnetic resonance imaging; GAD=glutamic acid decarboxylase; OGB=oligoclonal bands; JAK=janus kinase; HSCT=haematopoietic stem cell transplantation; HLH=haemophagocytic lymphostocytosis; ANA=antinuclear; IVIG=intravenous immunoglobulin; CT=computed tomography; CSF=cerebrospinal fluid; AD=autosomal dominant; AR=autosomal recessive. T=tolerated; B=benign; D=damaging; N=polymorphism; Het= heterozygous; Hom= Homozygous; Hemi= hemizyosity; XLR= X-linked recessive; XL= X-linked.

Patient number	Sex	Age (Years)	Gene	Nucleotide Change	Amino Acid Change	Predicted pathogenicity	Mode of inheritance/ Zygosity	Variant Classification	Clinical Features, laboratory investigations and treatment	Clinical impact of NIP and suspected diagnosis after genetic testing
17	F	18	<i>NLRP3</i>	c.2557A>G	p.Thr853Ala	T/B/D	AD/Het	3	<p>Clinical features: Recurrent episodes of encephalopathy, seizures, psychiatric symptoms, left homonymous quadrantanopia, diabetes, autoimmune thyroiditis. No other systemic symptoms or other organ involvement. Relapsing disease course.</p> <p>Investigations: MRI brain showed abnormal signal and atrophic changes in right occipital lobe with extension in right thalamus and mesiotemporal lobe. Atrophic changes subsequently extended to right cerebellar hemisphere and right parietal lobe. Positive GAD antibodies, negative other autoantibodies. No acute phase response.</p> <p>Treatment: IVIG</p>	Unclassified neuroinflammatory disease
			<i>NLRC4</i>	c.2785G>T	p.Ala929Ser	T/B/.	AD/Het	3		
			<i>RANBP2</i>	c.7172C>G	p.Thr2391Ser	T/B/N	AD/Het	3		
			<i>FBN2</i>	c.7181T>C	p.Ile2394Thr	T/B/N	AD/Het	3		
			<i>STX11</i>	c.9C>A	p.Asp3Glu	D/D/D	AR/Het	3		
			<i>TSC1</i>	c.2194C>T	p.His732Tyr	D/P/A	AD/Het	4		
			<i>NOTCH1</i>	c.4028C>T	p.Ala1343Val	T/P/D	AD/Het	3		
			<i>NOTCH1</i>	c.1981G>A	p.Gly661Ser	T/P/D	AD/Het	3		
			<i>POLG</i>	c.158_159insGCA	p.Gln55_Pro56insGln	././.	AD;AR/Het	3		
			<i>MEFV</i>	c.442G>C	p.Glu148Gln	D/D/P	AD;AR/Het	3		
			<i>RNF213</i>	c.4156G>A	p.Asp1386Asn	T/B/N	-/Het	3		
<i>DNASE2</i>	c.134C>G	p.Ala45Gly	T/P/N	-/Het	3					

18	M	15	<i>ADAR</i>	c.577C>G	p.Pro19 3Ala	D/D/D	AR;AD/Het	5	<p>Clinical features: Encephalitis triggered by influenza A, cutaneous leucocytoclastic vasculitis, peripheral lymphoedema.</p> <p>Investigations: MRI brain showed bilateral haemorrhagic foci and brain oedema. Negative autoantibodies, normal complement studies, modestly elevated ESR (20 mm/h; RR< 10 mm/h).</p> <p>Treatment: Corticosteroids and azathioprine.</p>	Likely monogenic interferonopathy.
			<i>CFHR5</i>	c.832G>A	p.Gly27 8Ser	D/D/N	AD/Het	3		
			<i>TGFBR2</i>	c.374del	p.K128 Sfs*34	./.	AD/Het	3		
			<i>PEX1</i>	c.3250A>G	p.Met10 84Val	T/P/D	AR/Het	3		
			<i>SPTAN1</i>	c.1303T>G	p.Ser43 5Ala	T/B/D	AD/Het	3		
			<i>POLG</i>	c.158_159insGCA	p.Gln55 _Pro56insGln	./.	AR;AD/Het	3		
			<i>RNF213</i>	c.5162C>T	p.Pro17 21Leu	T./N	-/Het	3		
		<i>LPIN2</i>	c.1801G>A	p.Glu60 1Lys	T/B/N	-/Het	3			
19	M	14	<i>FUCA1</i>	c.106C>T	p.Arg36 Cys	D/P/D	AR/Het	3	<p>Clinical features: Recurrent acute transverse myelitis, optic neuritis, hearing loss, choreoathetosis, development delay. No other systemic symptoms or other organ involvement. Chronic relapsing disease course.</p> <p>Investigations: MRI brain showed bilateral and symmetrical T1 hyperintense signal in the globi pallidi, bilateral mild engorgement of the deep medullary veins (more on the left) with</p>	Unclassified neuroinflammatory disease
			<i>BTD</i>	c.133G>A	p.Gly45 Arg	T/B/N	AR/Het	4		
			<i>PEX1</i>	c.1579A>G	p.Thr52 7Ala	T/B/D	AR/Het	3		
			<i>CLEC16A</i>	c.2945G>A	p.Ser98 2Asn	D/D/D	-/Het	3		
			<i>POLG</i>	c.158_159insGCAGCA	p.Gln55 _Pro56insGlnGln	./.	AD;AR/Hom	3		
			<i>LONP1</i>	c.10A>G	p.Ser4Gly	T/B/D	AR/Het	3		
			<i>MEFV</i>	c.442G>C	p.Glu14 8Gln	D/D/P	AD;AR/Het	3		
		<i>HSD17B4</i>	c.272G>A	p.Gly91 Glu	D/D/D	AR/Het	3			

									some associated haemorrhagic foci, generalised brain parenchymal swelling. Negative autoantibodies and CSF OGB negative. No acute phase response. Treatment: IVIG, corticosteroids, rituximab	
20	F	3	<i>DARS</i>	c.1391C>T	p.Pro464Leu	T/D/D	AR/Het	4	Clinical features: Subcutaneous nodules, progressive ataxia, muscle weakness, lipodystrophy. Investigations: MRI brain revealed widespread leucoencephalopathy. Negative autoantibody screen and no acute phase response. Significant upregulation of interferon induced gene expression. Treatment: corticosteroids, oral JAK1/JAK2 inhibitor, mycophenolate mofetil..	Likely monogenic interferonopathy
			<i>PRX</i>	c.1574T>C	p.Val525Ala	T/B/N	AD;AR/Het	3		
			<i>PRX</i>	c.133C>G	p.Arg45Gly	D/P/D	AD;AR/Het	3		
			<i>CBS</i>	c.833T>C	p.Ile278Thr	D/D/A	AR/Het	3		
			<i>FBN2</i>	c.6598A>G	p.Met2200Val	T/B/D	AD/Het	3		
			<i>MYH11</i>	c.3949C>A	p.Leu1317Ile	T/P/D	AD/Het	3		
			<i>NDUFS3</i>	c.475G>C	p.Val159Leu	T/B/D	AR/Het	3		
			<i>PLCG2</i>	c.2542C>T	p.Leu848Phe	T/D/D	AD/Het	3		
			<i>PRKG1</i>	c.1421A>T	p.Tyr474Phe	D/B/D	AD/Het	3		
			<i>RNF213</i>	c.5114C>A	p.Thr1705Lys	D/.D	-/Het	3		
			<i>TNFAIP3</i>	c.1105G>A	p.Ala369Thr	T/B/N	AD/Het	3		
21	M	8	<i>IL1RN</i>	c.379G>A	p.Ala127Thr	T/B/N	AD;AR/Het	3	Clinical features: Febrile episode followed by refractory seizures, progressive four limb motor	Autoimmune lymphoproliferative syndrome.
			<i>LONP1</i>	c.70C>A	p.Leu24Met	D/D/N	AR/Het	3		

			<i>MFN2</i>	c.58C>T	p.His20 Tyr	T/B/D	AD;AR/Het	3	<p>dystonic disorder following infectious gastroenteritis. History of frequent chest infections.</p> <p>Investigations: MRI brain showed marked atrophy and signal changes followed by cystic degeneration on subsequent scans in basal ganglia, internal capsule and midbrain. Negative autoantibody screen and no acute phase response.</p> <p>Treatment: Corticosteroids</p>	Referred to Immunology for consideration of HSCT.
			<i>PEX13</i>	c.661C>G	p.Leu22 1Val	T/B/D	AR/Het	3		
			<i>POLR3A</i>	c.3499G>C	p.Val11 67Leu	T/P/D	AR/Het	3		
			<i>TGFBI</i>	c.C829C>G	p.Leu27 7Val	T/B/D	AD/Het	3		
			<i>USP18</i>	c.974A>G	p.Asn32 5Ser	T/B/N	AR/Het	3		
			<i>COL3A1</i>	c.1804C>A	p.Pro60 2Thr	T/P/D	AD/Het	3		
			<i>TMEM173</i>	c.937G>A	p.Ala31 3Thr	T/B/N	AD/Het	3		
			<i>C5</i>	c.3051G>C	p.Glu10 17Asp	D/D/D	AD/Het	3		
			<i>FAS</i>	c.517G>A	p.Glu17 3Lys	T/B/N	AD/Het	4		
22	M	18	<i>ERCC3</i>	c.2080G>A	p.Ala69 4Thr	T/B/D	AR/Het	3	<p>Clinical features: Recurrent seizures, progressive ataxia, dysarthria, loss of mobility, learning difficulties, necrotising pneumonia.</p> <p>Investigations: MRI brain changes suggestive of chronic lymphocytic inflammation with pontine perivascular enhancement responsive to steroids (CLIPPERS) syndrome. ANA/dsDNA and complement studies normal. Blood film no</p>	Primary HLH diagnosed posthumously
			<i>BTD</i>	c.1171C>T	p.Pro39 1Ser	T/B/N	AR/Het	3		
			<i>ERCC8</i>	c.170G>A	p.Arg57 Lys	T/B/D	AR/Het	3		
			<i>FBN2</i>	c.976C>T	p.Pro32 6Ser	T/B/D	AD/Hom	3		
			<i>RRM2B</i>	c.44C>T	p.Pro15 L	././	AD;AR/Het	3		
			<i>PRF1</i>	c.1621del	p.M541 Cfs*71	././	AR/Het	4		
			<i>PRF1</i>	c.82C>T	p.Arg28 Cys	D/P/N	AR/Het	4		
			<i>NUBPL</i>	c.545T>C	p.Val18 2Ala	D/P/D	AR/Het	3		

			<i>MYO5A</i>	c.5065G>A	p.Val1689Ile	T/B/D	AR/Het	3	lymphocyte vacuolation. Muscle biopsy and other metabolic disease tests-normal. Brain biopsy chronic white matter disease with dense macrophage infiltrate. History of occasional cytopaenias. Treatment: IVIG, mycophenolate mofetil, azathioprine, rituximab, natalizumab.	
			<i>POLG</i>	c.158_159insGCA	p.Gln55_Pro56insGln	./.	AD;AR/Het	3		
			<i>TSC2</i>	c.4524_4526del	p.Phe1510del	./.	AD/Het	3		
			<i>MYH11</i>	c.4156A>G	p.Thr1386Ala	T/B/D	AD/Het	3		
			<i>CTC1</i>	c.974A>G	p.Ser83Thr	D/D/D	AR/Het	3		
23	F	12	<i>DGUOK</i>	c.462T>A	p.Asn154Lys	D/D/D	AR/Het	4	Clinical features: Facial lipodystrophy, recurrent seizures, progressive myoclonus, occasional fevers, no rashes or articular symptoms. Investigations: MRI brain no progressive white matter disease. Negative autoantibody screen. Treatment: rituximab, mycophenolate mofetil, IVIG and methotrexate.	Unclassified neuroinflammatory disease
			<i>MVK</i>	c.1129G>A	p.Val377Ile	T/B/A	AD;AR/Het	4		
			<i>RANBP2</i>	c.6362A>G	p.Gln2121Arg	T/D/D	AD/Het	3		
			<i>RANBP2</i>	c.6680A>G	p.Tyr2227Cys	D/D/D	AD/Het	3		
			<i>TGFBR2</i>	c.374del	p.Lys128Sfs*34	./.	AD/Het	3		
			<i>CFI</i>	c.1657C>T	p.Pro553Ser	T/B/N	AD;AR/Het	3		
			<i>PRF1</i>	c.755A>G	p.Asn252Ser	T/B/N	AR/Het	3		
			<i>PLCG2</i>	c.82A>T	p.Met28Leu	T/P/D	AD/Het	3		
			<i>IRF8</i>	c.724T>C	p.Tyr242His	D/P/D	AD/Het	3		
			<i>RNF213</i>	c.1208_1210del	p.Gly405del	./.	-/Het	3		
			<i>USP18</i>	c.974A>G	p.Asn325Ser	T/B/N	AR/Het	3		

24	F	10	<i>YYIAP1</i>	c.516G>C	p.Met17 2Ile	T/D/D	AR/Het	3	<p>Clinical features: Right sided visual loss secondary to long standing optic disc swelling and optic neuritis. No systemic symptoms or other organ involvement.</p> <p>Investigations: MRI brain scan, nonprogressive white matter disease (non-consistent with MS). Negative autoantibody profile and no acute phase response.</p> <p>Treatment: corticosteroids.</p>	Unclassified neuroinflammatory disease
			<i>LYST</i>	c.1686G>C	p.Gln56 2His	D/P/D	AR/Het	3		
			<i>RANBP2</i>	c.7172C>G	p.Thr23 91Ser	T/B/N	AD/Het	3		
			<i>PEXI</i>	c.2528G>A	p.Gly84 3Asp	D/D/A	AR/Het	4		
			<i>ATPAF2</i>	c.511G>A	p.Val17 1Met	T/B/D	AR/Het	3		
			<i>GFAP</i>	c.650G>A	p.Arg21 7Gln	T/B/D	AD/Het	3		
			<i>TRIM28</i>	c.2183CT	p.Thr72 8Ile	T/B/N	AD/Het	3		
			<i>RBCK1</i>	c.703G>A	p.Glu23 5Lys	T/B/D	AR/Het	3		
			<i>USP18</i>	c.506C>T	p.Thr16 9Met	T/B/N	AR/Het	3		
			<i>ARSA</i>	c.*96A>G	-	././	AR/Het	3		
<i>ARSA</i>	c.1055A>G	p.Asn35 2Ser	T/B/P	AR/Het	3					
25	F	15	<i>ATP7B</i>	c.3207C>A	p.His10 69Gln	D/D/A	AR/Het	4	<p>Clinical features: Progressive polyneuropathy, glaucoma, spinal cord tethering, atrial septal defect, ventricular septal defect, proptosis, precocious telarche, keratosis pilaris.</p> <p>Investigations: MRI brain and spine showed diffuse thickening of the nerve roots with Meckel's</p>	Unclassified neuroinflammatory disease
			<i>MASP2</i>	c.1243G>A	p.Asp41 5Asn	T/B/D	AR/Het	3		
			<i>CPT2</i>	c.1763C>G	p.Ser58 8Cys	D/D/D	AD;AR/Het	3		
			<i>LYST</i>	c.5518T>G	p.Ser18 40Ala	T/B/D	AR/Het	3		
			<i>DGUOK</i>	c.4G>T	p.Ala2Ser	T/B/N	AR/Het	3		
			<i>RANBP2</i>	c.6362A>G	p.Gln21 21Arg	T/D/D	AD/Het	3		

			<i>RANBP2</i>	c.6680A>G	p.Tyr22 27Cys	D/D/D	AD/Het	3	caves, foramina ovale and the jugular foramina, the cauda equina, in all spinal exit foramina, the lumbar plexus and the right sciatic nerve. Negative autoantibody profile and no acute phase response. Negative CSF OGB and normal levels of CSF neopterin. Treatment: corticosteroids and IVIG.	
			<i>TGFBR2</i>	c.374del	p.Lys12 8Sfs*34	././	AD/Het	3		
			<i>MYLK</i>	c.3706A>G	p.Met12 36Val	T/B/N	AD/Het	3		
			<i>GFM1</i>	c.1775A>T	p.Xaa59 2Leu	././N	AR/Het	3		
			<i>AIMP1</i>	c.7C>T	p.Prp3S er	D/./N	AR/Het	3		
			<i>C6</i>	c.2435C>T	p.Thr81 2Ile	D/D/D	-/Het	3		
			<i>C6</i>	c.1555G>A	p.Asp51 9Asn	D/D/D	-/Het	3		
			<i>TGFBI</i>	c.1954G>C	p.Glu65 2Gln	D/B/D	AD/Het	3		
			<i>POLRIC</i>	c.944C>T	p.Ala31 5Val	D/P/N	AR/Het	3		
			<i>NEFL</i>	c.1576G>A	p.Glu52 6Lys	./B/.	AD;AR/Het	3		
			<i>ERCC6</i>	c.3659C>T	p.Thr12 20Ile	T/B/N	AD;AR/Het	3		
			<i>GALC</i>	c.1403C>G	p.Thr46 8Ser	D/D/D	AR/Het	3		
			<i>POLG</i>	c.58_159in sGCAGCA	p.Gln55 _Pro56i nsGlnGln	././	AD;AR/Het	3		
			<i>POLG</i>	c.125G>A	p.Arg42 Gln	T/B/N	AD;AR/Het	3		
			<i>TSC2</i>	c.3914C>T	p.Pro13 05Leu	T/B/N	AD/Het	3		
			<i>MEFV</i>	c.586G>T	p.Gly19 6Trp	D/B/N	AD;AR/Het	3		

			<i>NOD2</i>	c.1622G>A	p.Arg54 1Gln	T/B/N	AD;Mu/Het t	3		
26	M	3	<i>SH2DIA</i>	c.163C>T	p.Arg55 Xaa	././A	XLR/Het	5	<p>Clinical features: Seizures, acute lethargy, incoherent speech, aphasia, neutropaenia. Chronic relapsing disease course.</p> <p>Investigations: MRI brain showed widespread bilateral white matter disease progressive over time with brain volume loss. Brain biopsy showed non-specific lymphocytic infiltrate. Negative autoantibody profile and no acute phase response. Negative CSF OGB</p> <p>Treatment: IVIG, steroids, cyclophosphamide. plasma exchange.</p>	X-linked lymphoproliferative disease. Underwent allogeneic HSCT. Sibling diagnosed with XLP-type 1 and underwent HSCT too.
			<i>RANBP2</i>	c.6362A>G	p.Gln21 21Arg	T/D/D	AD/Het	3		
			<i>RANBP2</i>	c.7172C>G	p.Thr23 91Ser	T/B/N	AD/Het	3		
			<i>C6</i>	c.542C>T	p.Thr18 1Ile	T/B/N	-/Het	3		
			<i>NOTCH1</i>	c.3664G>A	p.Val12 22Met	T/B/D	AD/Het	3		
			<i>POLR3A</i>	c.1745G>T	p.Arg58 2Leu	D/B/D	AR/Het	3		
			<i>DNASE1</i>	c.105G>C	p.Glu35 Asp	T/B/D	AD/Het	3		
			<i>NLRP12</i>	c.1855G>C	p.Glu61 9Gln	D/D/D	AD/Het	3		
			<i>CBS;CBS L</i>	c.1105C>T	p.Arg36 9Cys	D/D/D	AR/Het	3		
<i>USP18</i>	c.1115G>T	p.Cys37 2Phe	D/B/N	AR/Het	3					
27	F	17mon ths	<i>SKI</i>	c.1163C>T	p.Ala38 8Val	T/B/N	AD/Het	3	<p>Clinical features: Necrotising encephalopathy with seizures leading to death preceded by chest infection.</p> <p>Investigations: MRI brain showed oedema, no focal lesions. Negative autoantibody profile, cytopaenias, no acute phase response.</p>	Unclassified neuroinflammatory disease
			<i>RANBP2</i>	c.7172C>G	p.Thr23 91Ser	T/B/N	AD/Het	3		
			<i>BTD</i>	c.1171C>T	p.Pro39 1Ser	T/B/N	AR/Het	3		
			<i>TGFBR2</i>	c.374del	p.Lys12 8SERfs *34	././.	AD/Het	3		
			<i>COQ2</i>	c.64A>T	p.Arg22 Xaa	././A	AD;AR/Het t	3		

			<i>MEFV</i>	c.1772T>C	p.Ile591 Thr	T/B/N	AD;AR/Het	3	Negative CSF OGB. Treatment: corticosteroids and IVIG, plasma exchange with no response.	
			<i>COX10</i>	c.1291C>T	p.Arg43 1Trp	D/P/N	AR;Mi/Het	3		
			<i>STXBP2</i>	c.1034C>T	p.Thr34 5Mey	D/D/D	-/Het	4		
			<i>PRF1</i>	c.272C>T	p.Ala91 Val	D/D/D	AR/Het	3		
			<i>USP18</i>	c.1097T>C	p.Val36 6Ala	D/P/N	AR/Het	3		
			<i>TRNT1</i>	c.1057- 7C>G	p.introni c	././.	AR/Het	5		
28	M	8	<i>ISG15</i>	c.388C>T	p.Pro13 0Ser	T/P/N	AR/Het	3	Clinical features: Refractory epilepsy. Mild skin rashes occasional fevers. Chronic relapsing disease course. Investigations: Brain MRI showed white matter disease in the left temporal pole, both mesial frontal lobes, left insular, left peritrigonal and parietal regions with diffuse cortical atrophy particularly in the left frontal and perirolandic regions. Brain biopsy showed chronic inflammatory process affecting both white and grey matter with no fibrinoid necrosis of leukocytoclasia.	Muckle Wells syndrome (Cryopyrin associated periodic syndrome). Referred to rheumatology for consideration of starting IL-1 blockade therapy.
			<i>PEX10</i>	c.611G>A	p.Arg20 4His	T/B/N	AR/Het	3		
			<i>C8A</i>	c.1331G>A	p.Arg44 4His	D/D/D	AR/Het	3		
			<i>NLRP3</i>	c.214G>A	p.Val72 Met	D/D/N	AD/Het	4		
			<i>RANBP2</i>	c.1258A>G	p.Thr42 0Ala	T/B/N	AD/Het	3		
			<i>ERCC3</i>	c.847C>T	p.Arg28 3Cys	D/P/D	AR/Het	3		
			<i>CYP27A1</i>	c.491G>C	p.Arg16 4Pro	D/D/D	AR/Het	3		
			<i>GATA2</i>	c.595G>A	p.Gly19 9Arg	D/D/D	AD/Het	3		
			<i>ITPR3</i>	c.4364G>A	p.Arg14 55His	T/D/D	AR/Het	3		
			<i>SAMD3</i>	c.731del	p.Leu24 4Yfs*16	././.	-/Het	3		
			<i>FAM126A</i>	c.1171G>C	p.Gly39 1Arg	D/B/D	AR/Het	3		

			<i>ERCC6</i>	c.4315G>C	p.Ala14 39Pro	D/D/D	AD;AR/Het	3	Positive CSF OGB and elevated neopterin 211 nmol/l (RR< 65 nmol/l). Negative antibodies for Myelin Oligodendrocyte Glycoprotein /Aquaporin 4/ ANA/dsDNA. Treatment: Corticosteroids and mycophenolate mofetil.	
			<i>STAT2</i>	c.2478G>T	p.Gln82 6His	D/B/N	AR/Het	3		
			<i>PMP22</i>	c.353C>T	p.Thr11 8Met	D/D/A	AD;AR/Het	4		
			<i>NOTCH3</i>	c.1490C>T	p.Ser49 7Leu	T/B/D	AD/Het	3		
			<i>SLC2A10</i>	c.1057C>G	p.Leu35 3Val	T/B/N	AR/Het	3		
29	M	15	<i>NDUFS2</i>	c.1004A>T	p.Glu33 5Val	D/P/P	AR/Het	3	Clinical features: Recurrent episodes of occipital headache, bilateral arm weakness, visual symptoms, collapse. Investigations: MRI brain showed patchy bilateral and asymmetric white matter lesions in the cerebral hemispheres and posterior fossa with some attenuation of the posterior circulation vessels on MRA. Catheter angiography cerebral and visceral normal. No spinal pathology. Brain biopsy showed multiple foci of chronic inflammation comprising predominantly T-lymphocytes, present in the cortex, white matter and	Primary HLH
			<i>RANBP2</i>	c.5756G>A	p.Gly19 19Asp	T/B/B	AD/Het	3		
			<i>RANBP2</i>	c.6362A>G	p.Gln21 21Arg	T/D/D	AD/Het	3		
			<i>RANBP2</i>	c.6680A>G	p.Tyr22 27Cys	D/D/D	AD/Hom	3		
			<i>RANBP2</i>	c.7172C>G	p.Thr23 91Ser	T/B/B	AD/Het	3		
			<i>RANBP2</i>	c.7669A>G	p.Asn25 57Asp	T/B/B	AD/Het	3		
			<i>TGFBR2</i>	c.449del	p.Lys15 3Serfs* 34	././.	AD/Hom	3		
			<i>FBN2</i>	c.8351C>T	p.Pro27 84Leu	T/B/B	AD/Het	3		
			<i>CSF1R</i>	c.2891_289 2insC	p.Gln96 5Alafs* 11	././.	AD/Hom	3		
			<i>PEX6</i>	c.2219T>C	p.Leu74 0Pro	D/D/D	AD;AR/Het	3		
			<i>PRF1</i>	c.731T>G	p.Leu24 4Arg	D/D/D	AR/Het	4		

			<i>PRF1</i>	c.694C>T	p.Arg23 2Cys	D/D/D	AR/Het	4	<p>possibly on leptomeningeal surface in perivascular but no obvious evidence of vasculitis. Occasional foci show features of possible early granulomas, but there is no necrosis. RNA sequencing for identification of any pathogens on brain biopsy tissue was negative. Tuberculosis PCR and extended culture negative. Abnormal perforin expression and NK cell killing activity. CSF OGB negative; raised neopterin 211 (RR < 65 nmol/L). Normal complement studies, negative autoantibodies including MOG/Aq4. Mannose binding lectin deficient.</p> <p>Treatment: Corticosteroids.</p>	
			<i>PSTPIP1</i>	c.79C>T	p.R27W	D/./.	AD/Het	3		
			<i>DNASE1</i>	c.460C>G	p.P154 A	D/B/B	AD/Het	3		
			<i>MEFV</i>	c.442G>C	p.E148 Q	D/D/P	AD;AR/Het	3		
			<i>USP18</i>	c.974A>G	p.N325 S	T/B/B	AR/Het	3		
			<i>DARS2</i>	c.228- 21T>C	p.introni c	././.	AR/Hom	4		
			<i>DARS2</i>	c.228-20_ -21insC	p.introni c	././.	AR/Het	4		
30	F	12	<i>CFHR5</i>	c.Ala480dup	p.Glu16 3Argfs* 34	././.	AD/Hom	4	<p>Clinical features: Short history of fever and headache followed by rapid deterioration of conscious level and evidence raised ICP. No systemic symptoms or other organ involvement.</p>	Unclassified neuroinflammatory disease
			<i>CFHR5</i>	c.622T>C	p.Cys20 8Arg	D/D/N	AD/Het	3		
			<i>LYST</i>	c.8806G>A	p.Val29 36Ile	T/B/D	AR/Het	3		
			<i>RANBP2</i>	c.7172C>G	p.Thr23 91Ser	T/B/N	AD/Het	3		

			<i>CFI</i>	c.1555G>A	p.Asp51 9Asn	D/D/D	AD;AR/Het	3	Bilateral papillitis and/or papilloedema. Investigations: MRI brain suggested fulminant presumed ADEM. Biopsy – no vasculitis, monocytic infiltrate, no marked histochemical evidence of demyelination. Negative autoantibody profile and no acute phase response. Negative CSF OGB. Treatment: Required EVD and decompressive craniectomy.	
			<i>CFI</i>	c.1019T>C	p.Ile340 Thr	D/P/N	AD;AR/Het	3		
			<i>PEX7</i>	c.377A>C	p.Gln12 6Pro	T/P/D	AR/Het	3		
			<i>GALC</i>	c.334A>G	p.Thr11 2Ala	T/D/D	AR/Het	4		
			<i>NDUFAF1</i>	c.958G>A	p.Glu32 0Lys	T/B/N	AR/Het	3		
			<i>POLG</i>	c.158_159insGCA	p.Gln55 _Pro56insGln	././.	AD;AR/Hom	3		
			<i>C3</i>	c.4855A>C	p.Ser16 19Arg	T/P/N	AD;AR/Het	3		
			<i>TRIM28</i>	c.1180G>C	p.Asp39 4His	D/D/D	AD/Het	3		
			<i>USP18</i>	c.974A>G	p.Asn32 5Ser	T/B/N	AR/Het	3		
31	F	8	<i>PEX10</i>	c.435G>A	p.Met14 5Ile	T/B/N	AR/Het	3	Clinical features: Severe progressive retinal ischaemia and retinal angiopathy. Investigations: MRI brain non-specific stable white matter disease. Negative autoantibody profile. No acute phase response. Treatment: Nil	POLG2 related metabolic disorder. Referral to metabolic team and further metabolic test investigation were organised.
			<i>C8B</i>	c.1505C>T	p.Ser50 2Phe	D/D/D	AR/Het	3		
			<i>YYIAP1</i>	c.1157T>C	p.Ile386 Thr	D/B/B	AR/Het	3		
			<i>HSD17B4</i>	c.1192T>C	p.Ser39 8Pro	T/B/D	AR/Het	3		
			<i>PSMB8</i>	c.220A>T	p.Thr74 Ser	D/D/D	AR/Het	3		
			<i>SPTAN1</i>	c.1688T>C	p.Met56 3Thr	T/B/D	AD/Het	3		
			<i>SLC29A3</i>	c.7G>A	p.Val3Ile	T/B/N	AR/Het	3		

			<i>PEX16</i>	c.760G>C	p.Val25 4Leu	T/B/N	AR/Het	3		
			<i>POLG2</i>	c.1105A>G	p.Arg36 9Gly	D/D/D	AD/Hom	4		
			<i>NLRP12</i>	c.2222A>G	p.Asn74 1Ser	T/B/N	AD/Het	3		
			<i>MEFV</i>	c.442G>C	p.Glu14 8Gln	D/D/P	AD;AR/Het	3		
			<i>USP18</i>	c.974A>G	p.Asn32 5Ser	T/B/N	AR/Het	3		
32	F	10	<i>C8A</i>	c.1454G>A	p.Arg48 5His	D/B/P	AR/Het	3	<p>Clinical features: Recurrent fevers with acute phase response, arthralgia, aseptic meningitis.</p> <p>Investigations: MRI brain showed non progressive white matter disease. Negative autoantibody profile and no systemic symptoms or other organ involvement.</p> <p>Treatment: corticosteroids.</p>	<p>Autoinflammation, antibody deficiency, and immune dysregulation syndrome (APLAID). Family screening, consideration of IL-1 blockade.</p>
			<i>CLCN2</i>	c.704G>A	p.Arg23 5Gln	D/D/D	AD;AR/Het	3		
			<i>PEX7</i>	c.377A>C	p.Gln12 6Pro	T/P/D	AR/Het	3		
			<i>MPLKIP</i>	c.253G>C	p.Gln85 Arg	D/B/N	AR/Het	3		
			<i>ELN</i>	c.1861G>A	p.Ala62 1Thr	D/B/N	AD/Het	3		
			<i>TNFRSF1A</i>	c.1343C>T	p.Prp44 8Leu	T/B/N	AD/Het	3		
			<i>STAT2</i>	c.2473G>T	p.Gly82 5Cys	T/B/N	AR/Het	3		
			<i>POLG</i>	c.158_159insGCA	p.Gln55 _Pro56insGln	././	AD;AR/Het	3		
			<i>POLG</i>	c.156_158del	p.Gln55 del	././	AD;AR/Het	3		
			<i>POLG</i>	c.125G>A	p.Arg42 Gln	T/B/N	AD;AR/Het	3		
			<i>PLCG2</i>	c.1444T>C	p.Tyr48 2His	T/B/D	AD/Het	4		

			<i>PLCG2</i>	c.1712A>G	p.Asn571Ser	D/B/D	AD/Het	4		
			<i>CBS; CBS L</i>	c.833T>C	p.Ile278Thr	D/D/A	AR/Het	4		
			<i>PEX26</i>	c.728C>T	p.Ala243Val	T/B/N	AR/Het	3		
			<i>USP18</i>	c.1097T>C	p.Val366Ala	D/D/N	AR/Het	3		
			<i>USP18</i>	c.1115G>T	p.Cys372Phe	D/B/N	AR/Het	3		
33	M	9	<i>C8A</i>	c.1724C>T	p.P575L	T/B/P	AR/Het	3	<p>Clinical features: Left sided squint and vision loss. Left sided hemiplegia. No systemic symptoms or other organ involvement.</p> <p>Investigations: MRI brain showed bilateral symmetrical cortical and subcortical lesions in the parieto occipital lesions affecting both grey and white matter disease with associated oedema and haemorrhagic transformation. Brain biopsy suggested chronic inflammatory disorder with perivascular component. Negative CSF OGB. Negative autoantibody profile. Primary HLH functional</p>	Folate receptor deficiency
			<i>NDUFS2</i>	c.58C>A	p.P20T	D/B/P	AR/Het	3		
			<i>LYST</i>	c.8368A>C	p.K2790Q	D/B/P	AR/Het	4		
			<i>RANBP2</i>	c.8842A>C	p.S2948R	T/P/N	AD/Het	3		
			<i>TGFBR2</i>	c.374del	p.Lys128Serfs*34	./.	AD/Hom	3		
			<i>CFI</i>	c.1217G>A	p.Arg406His	T/P/P	AD;AR/Het	3		
			<i>OTULIN</i>	c.439C>T	p.Pro147Ser	T/B/N	AR/Het	3		
			<i>FBN2</i>	c.2260G>A	p.Gly754Ser	T/P/D	AD/Het	3		
			<i>TGFBI</i>	c.805C>T	p.Leu269Phe	D/D/D	AD/Het	3		
			<i>PHYH</i>	c.85C>T	p.Pro29Ser	T/B/P	AR/Het	3		
			<i>GALC</i>	c.49G>A	p.Ala17Thr	T./P	AR/Het	3		
<i>NDUFAF1</i>	c.941C>G	p.Ala314Gly	D/P/P	AR/Het	3					

			<i>POLG</i>	c.158_159insGCA	p.Gln55_Pro56insGln	./.	AD;AR/Hom	3	assays normal. Treatment: corticosteroids and cyclophosphamide, mycophenolate mofetil.	
			<i>TRAP1</i>	c.2053G>A	p.Asp685Asn	T/D/D	-/Het	3		
			<i>GFAP</i>	c.883G>A	p.Asp295Asn	D/D/P	AD/Het	3		
			<i>MEFV</i>	c.442G>C	p.Glu148Gln	D/D/P	AD;AR/Het	3		
			<i>PRX</i>	c.944G>A	p.Arg315Gln	T/B/D	AD;AR/Het	3		
			<i>MLC1</i>	c.628G>A	p.Val210Ile	T/B/D	AR/Het	3		
			<i>FOLR1</i>	c.493+2T>C	p.intronic	./.	AR/Hom	4		
34	F	21	<i>DARS2</i>	c.1257G>A	p.Met419Ile	T/B/N	AR/Het	3	Clinical features: Chorea. No other symptoms or organ involvement. Imaging: MRI brain showed progressive white matter disease. Autoantibody screen negative and infections as trigger excluded. Treatment: IVIG, corticosteroids, mycophenolate mofetil.	Unclassified neuroinflammatory disease
			<i>NOTCH1</i>	c.3836G>A	p.Arg1279His	T/B/D	AD/Het	3		
			<i>EXOSC8</i>	c.815G>C	p.Ser272Thr	T/P/D	AR/Het	5		
			<i>POLG</i>	c.156_158del	p.Gln55del	./.	AD;AR/Hom	3		
			<i>GFAP</i>	c.1288C>T	p.Arg430Cys	D/P/D	AD/Het	3		
			<i>POLG2</i>	c.562G>C	p.Gly188Arg	D/D/D	AD/Het	3		
			<i>PRX</i>	c.1568T>C	p.Leu523Pro	T/B/N	AD;AR/Het	3		
			<i>PRX</i>	c.1483G>C	p.Glu495Gln	T/B/D	AD;AR/Het	3		
			<i>USP18</i>	c.974A>G	p.Asn325Ser	T/B/N	AR/Het	3		

35	M	9	<i>STXBP2</i>	c.1034C>T	p.Thr34 5Met	D/D/D	AD;AR/het	4	<p>Clinical features: Enterocolitis, headache, cognitive decline, HLH.</p> <p>Investigations: MRI brain showed white matter disease non progressive. Negative autoantibody screen and no acute phase response.</p> <p>Treatment: Corticosteroids, IVIG, ciclosporin</p>	Unclassified neuroinflammatory disease with HLH
			<i>MFN2</i>	c.58C>T	p.His20 Tyr	T/B/D	AR/Het	3		
			<i>YYIAP1</i>	c.169C>T	p.Leu57 Phe	T/D/D	AD/Hom	3		
			<i>RANBP2</i>	c.7499C>T	p.Thr25 00Ile	D/B/N	AR/Het	3		
			<i>SKIV2L</i>	c.3279G>C	p.Glu10 93Asp	D/D/D	AR/Het	3		
			<i>NOTCH1</i>	c.4129C>T	p.Pro13 77Ser	T/B/N	AD/Het	3		
			<i>PLCG2</i>	c.1712A>G	p.Asn57 1Ser	D/B/D	AD/Het	3		
			<i>CTCI</i>	c.2162G>C	p.Gly72 Ala	T/B/N	AR/Het	3		
			<i>CTCI</i>	c.1241G>C	p.Gly41 4Ala	T/D/D	AR/Het	3		
36	M	1	<i>RNASEH2B</i>	c.179T>G	p.Leu60 Arg	D/D/A	AR/Het	5	<p>Clinical features: Neonatal meningoencephalitis, recurrent seizures, development delay.</p> <p>Investigations: MRI brain showed meningoencephalitis. CSF lymphocytosis and raised neopterin (105 nmol/IRR< 65 nmol/l), bilateral widespread white matter disease, normal XIAP expression, negative screening for congenital infection. Negative autoantibody profile.</p>	Aicardi Goutières syndrome (AGS) type 2. Family screening, consideration of JAK inhibition treatment
			<i>RNASEH2B</i>	c.529G>A	p.Ala17 7Ter	T/D/A	AR/Het	5		
			<i>SDHB</i>	c.487T>C	p.Ser16 3Pro	T/B/A	AD/Het	3		
			<i>C8B</i>	c.1625C>T	p.Thr54 2Ile	T/B/N	AR/Het	3		
			<i>NLRC4</i>	c.1163G>A	p.Arg38 8Gln	T/B/.	AD/Het	3		
			<i>RANBP2</i>	c.5941T>A	p.Ser19 81Thr	T/B/N	AD/Het	3		
			<i>CFI</i>	c.1322A>G	p.Lys44 1Arg	T/B/N	AD;AR/Het	3		
			<i>ITPR3</i>	c.626A>G	p.Glu20 9Gly	D/D/D	AR/Het	3		

			<i>PEX16</i>	c.760G>C	p.Val254Leu	T/B/N	AR/Het	3	Abnormal liver function tests. Treatment: Corticosteroids	
			<i>POLG</i>	c.158_159insGCAGCA	p.Gln55_Pro56insGlnGln	./.	AD;AR/Hom	3		
			<i>POLG</i>	c.125G>A	p.Arg42Gln	T/B/N	AD;AR/Het	3		
			<i>DNASE1</i>	c.503C>T	p.Ala168Val	D/P/D	AD/Het	3		
			<i>PRX</i>	c.4077_4079del	p.Glu1361del	./.	AD;AR/Het	3		
			<i>XIAP</i>	c.1429G>A	p.Ala477Thr	D/D/D	XLR/Hemi	3		
37	F	10	<i>SCN9A</i>	c.2215A>G	p.Ile739Val	D/P/D	AD;AR/Het	4	Clinical features: Opsoclonus myoclonus and neuroblastoma in infancy, lupus like disease with recurrent arthritis, cutaneous lesions, malar rash. Investigations: MRI brain widespread white matter disease. Positive ANA and dsDNA, Aq4 antibodies. Treatment: corticosteroids and mycophenolate mofetil.	Unclassified neuroinflammatory disease
			<i>CFHR5</i>	c.136C>T	p.Pro46Ser	T/B/N	AD/Het	3		
			<i>SCN9A</i>	c.3734A>G	p.Asn1245Ser	D/D/D	AD;AR/Het	3		
			<i>DDX58</i>	c.212G>A	p.Arg71His	D/D/D	AD/Het	3		
			<i>STAT2</i>	c.685G>A	p.Glu229Lys	T/D/D	AR/Het	3		
			<i>ATP7B</i>	c.751C>T	p.His251Tyr	T/B/N	AR/Het	3		
			<i>TRAP1</i>	c.1073A>G	p.Glu358Gly	T/B/N	-/Het	3		
			<i>GFAP</i>	c.1288C>T	p.Arg430Cys	D/P/D	AD/Het	3		
			<i>RNF213</i>	c.6551A>G	p.Gln2184Arg	T/B/N	-/Het	3		
			<i>LPIN2</i>	c.1801G>A	p.Glu601Lys	T/B/D	-/Het	3		

			<i>PRX</i>	c.716C>T	p.Pro23 9Leu	T/P/D	AD;AR/ Het	3		
			<i>NEFL</i>	c.1414- 1C>T	p.introni c	././.	-/Hom	3		
38	M	17	<i>PLOD1</i>	c.1217C>T	p.Pro40 6Leu	D/D/D	AR/Het	3	Clinical features: Lupus like disease with skin rashes and arthralgia. Investigations: MRI brain showed progressive white matter disease, intracerebral calcification. Positive dsDNA antibodies. Treatment: corticosteroids.	Unclassified neuroinflammatory disease
			<i>RANBP2</i>	c.5941T>A	p.Ser19 81Thr	T/B/N	AD/Het	3		
			<i>ERCC3</i>	c.144G>C	p.Glu48 Asp	T/B/D	AR/Het	3		
			<i>COQ2</i>	c.64A>T	p.Arg22 Xaa	././A	AD;AR/ Het	3		
			<i>CSF1R</i>	c.1237G>A	p.Gly41 3Ser	T/P/N	AD/Het	3		
			<i>HFE</i>	c.193A>T	p.Ser65 Cys	D/D/A	AR/Het	4		
			<i>SLC17A5</i>	c.1375G>A	p.Val45 9Met	D/D/D	AR/Het	3		
			<i>PEX1</i>	c.2953C>T	c.Gky12 20Thr	D/D/D	AR/Het	3		
			<i>SUCLA2</i>	c.1220G>T	p.Arg40 7Leu	D/D/D	AR/Het	3		
			<i>POLG</i>	c.2492A>G	p.Tyr83 1Cys	T/D/A	AD;AR/ Het	3		
			<i>POLG</i>	c.158_166d el	p.Gln53 _Gln55d el	././.	AD;AR/ Het	3		
			<i>NOD2</i>	c.2722G>C	p.Gly90 8Arg	D/D/D	AR;Mu/ Het	3		
<i>POLG2</i>	c.1247G>C	p.Gly41 6Ala	T/D/D	AD/Het	3					
<i>RNF213</i>	c.11465G> T	p.Arg38 22Ile	D/D/D	-/Het	3					

			<i>RNASEH2A</i>	c.615T>A	p.Asp20 5Glu	T/B/D	AR/Het	3		
39	F	8	<i>TRNT1</i>	c.667A>G	p.Ile223 Val	T/P/D	AR/Het	5	Clinical features: Right sided hemiplegia, blurred vision, pyrexia, cytopaenias, seizures. No systemic symptoms or other organ involvement. Chronic progressive disease course. Investigations: CT diffuse cerebral oedema and swelling, MRI brain white matter disease. Negative autoantibody profile. Negative CSF OGB. Treatment: corticosteroids.	Unclassified neuroinflammatory disease
			<i>RANBP2</i>	c.2351G>A	p.Arg78 4Lys	T/B/N	AD/Het	3		
			<i>NDUFS1</i>	c.29T>C	p.Leu10 Pro	D/B/N	AR/Het	3		
			<i>CYP27A1</i>	c.673C>T	p.Arg22 5Cys	D/D/D	AR/Het	3		
			<i>MYLK</i>	c.2101G>A	p.Ala70 1Thr	T/B/N	AD/Het	3		
			<i>MYLK</i>	c.1684G>A	p.Glu56 2Lys	D/P/D	AD/Het	3		
			<i>TTC37</i>	c.860A>G	p.Lys28 7Arg	T/B/D	AR/Het	3		
			<i>FAM126A</i>	c.1555T>C	p.Ser51 9Pro	D/P/D	AR/Het	3		
			<i>NOTCH1</i>	c.4451A>G	p.Asn14 84Ser	T/B/D	AD/Het	3		
			<i>MYO5A</i>	c.5018C>T	p.Ser16 73Leu	D/P/D	AR/Het	3		
			<i>PSTPIP1</i>	c.80G>A	p.Arg27 Gln	D/.N	AD/Het	3		
			<i>POLG</i>	c.803G>C	p.Gly26 8Ala	D/D/D	AD;AR/Het	3		
			<i>POLG</i>	c.153_158del	p.Gln54 _Gln55del	./.	AD;AR/Het	3		
<i>PARN</i>	c.1102A>T	p.Ser36 8Cys	D/P/D	AD;AR/Het	3					
<i>MYH11</i>	c.5819C>A	p.Pro19 40Gln	D/B/D	AD/Het	3					

			<i>NOD2</i>	c.781G>T	p.Ala261Ser	T/B/N	AD;Mu/Het	3		
			<i>RNF213</i>	c.103G>A	p.Glu35Lys	T/B/N	-/Het	3		
			<i>RNF213</i>	c.7417G>A	p.Ala2473Thr	T/B/N	-/Het	3		
			<i>DNASE2</i>	c.611A>G	p.His204Arg	T/B/N	-/Het	3		
			<i>CST3</i>	c.88G>A	p.Gly30Ser	T/B/N	AD/Het	3		
			<i>PEX26</i>	c.130C>T	p.Leu44Phe	T/B/N	AR/Het	3		
			<i>USP18</i>	c.389G>A	p.Cys130Tyr	T/B/N	AR/Het	3		
			<i>NEFL</i>	4345+2C>T	p.Intronic	./.	AD;AR/Hom	3		
40	M	6	<i>STXBP2</i>	c.1621G>A	p.Gly541Ser	D/D/D	AR/Het	5	<p>Clinical features: Progressive ataxia, headaches, encephalopathy. No systemic symptoms or other organ involvement.</p> <p>Investigations: MRI brain showed progressive cerebellar white matter disease and dentate changes associated with cerebellar swelling and crowding of posterior fossa. Elevated CSF neopterin 95 (RR<65), negative CSF OGB, normal ESR and CRP. Negative autoantibody profile. Abnormal T-cell</p>	<p>Primary HLH. Referred to immunology and undergoing work up for HSCT</p>
			<i>STXBP2</i>	c.1247-1G>C	p.Intronic	././D	AR/Het	5		
			<i>PLOD1</i>	c.555G>T	p.Lys185Asn	T/B/D	AR/Het	3		
			<i>PEX11B</i>	c.13G>A	p.Val5Ile	./.	AR/Het	3		
			<i>COQ8A</i>	c.11T>A	p.Ile4Lys	T/D/D	AR/Het	3		
			<i>LYST</i>	c.3499G>A	p.Val1167Ile	T/B/N	AR/Het	3		
			<i>RANBP2</i>	c.5941T>A	p.Ser1981Thr	T/B/N	AD/Het	3		
			<i>IFIH1</i>	c.2863C>G	p.Gln955Glu	T/B/N	AD/Het	3		
			<i>CSF1R</i>	c.533G>C	p.Ser178Thr	T/B/N	AD/Het	3		

			<i>COL4A1</i>	c.C161C>T	p.Pro54 Leu	D/D/D	AD/Het	3	and NK cell degranulation assay.	
			<i>SAMHD1</i>	c.G1583G>A	p.Arg52 8Lys	T/B/N	AD;AR/Het	3	Treatment: mycophenolate mofetil, corticosteroids	
41	F	7	<i>IFIH1</i>	c.2336G>A	p.Arg77 9His	T/D/D	AD/Het	5	Clinical features: Severe developmental delay, past medical history of opsoclonus myoclonus and neuroblastoma, lupus like disease characterised by cutaneous vasculitis and a malar rash. Investigations: MRI brain showed wide spread white matter disease. Raised inflammatory markers and positive autoantibodies (ANA, anti-dsDNA). Treatment: mycophenolate mofetil, corticosteroids	AGS type 7. Started treatment with JAK inhibitor. Family counselling and genetic screening.
			<i>C2</i>	c.1109C>T	p.Ala37 0Val	T/B/N	AR/Het	3		
			<i>TSC1</i>	c.2285A>G	p.Asn76 2Ser	T/B/D	AD/Het	3		
			<i>POLG</i>	c.158_159insGCA	p.Gln55 _Pro56insGln	./.	AD;AR/Het	3		
			<i>CLEC16A</i>	c.2287G>A	p.Val76 3Met	T/D/D	-/Het	3		
			<i>ACOX1</i>	c.628C>T	p.Arg21 0Cys	D/D/D	AR/Het	3		
			<i>NEFL</i>	4345+2C>T	p.Intronic	./.	AD;AR/Hom	3		
42	F	13	<i>RAB27A</i>	c.550C>T	p.Arg18 4Xaa	././D	AR/Het	5	Clinical features: Strabismus, ataxia. Mild erythematous skin rashes, no fevers or other systemic symptoms. Investigations: MRI brain widespread progressive white matter disease in pons medulla and cerebellum. Negative autoantibody profile. No cytopaenias.	Griscelli syndrome. Referred to immunology and undergoing work up for HSCT
			<i>RAB27A</i>	c.259G>C	p.Ala87 Pro	D/D/A	AR/Het	5		
			<i>PEX10</i>	c.880A>G	p.Thr29 4Ala	T/D/D	AR/Het	3		
			<i>DGUOK</i>	c.125C>T	p.Ser42 Phe	D/D/D	AR/Het	3		
			<i>DGUOK</i>	c.218A>G	p.Gln73 Arg	D/D/D	AR/Het	3		
			<i>ITPR3</i>	c.626A>G	p.Glu20 9Gly	D/D/D	AR/Het	3		

			<i>SAMD3</i>	c.149T>C	p.Ile50Thr	D/D/D	-/Het	3	Negative CSF OGB. Abnormal T-cell and NK cell degranulation assay. Treatment: mycophenolate mofetil, corticosteroids	
			<i>UNC13D</i>	c.2243C>T	p.Ala748Val	T/P/D	-/Het	3		
			<i>TRIM28</i>	c.1073A>C	p.N358T	D/B/D	AD/Het	3		

eTable 7. Clinical features and class 3 genetic variants identified on Neuroinflammation gene panel (NIP) in 34 patients with suspected genetic neuroinflammatory disorders and unknown molecular diagnoses. MRI=magnetic resonance imaging; GAD=glutamic acid decarboxylase; OGB=oligoclonal bands; JAK=janus kinase; HSCT=haematopoietic stem cell transplantation; HLH=haemophagocytic lymphohistiocytosis; ANA=antinuclear; IVIG=intravenous immunoglobulin; CT=computed tomography; CSF=cerebrospinal fluid; AD=autosomal dominant; AR=autosomal recessive; Mu= mutation; SMu= somatic mutation; XL= X-linked; XLR= X-linked recessive; T=tolerated; B=benign; D=damaging; N=polymorphism; Het= heterozygous; Hom= Homozygous; Hemi= hemizygosity; ESR=erythrocyte sedimentation rate; CRP=C-reactive protein.

Patient number		Sex	Age (Years)	Gene	Nucleotide Change	Amino Acid Change	Predicted pathogenicity	Mode of inheritance/ Zygosity	Variant Classification	Clinical Features, investigations and treatment	Clinical impact of NIP and suspected diagnosis after genetic testing
43		F	19	<i>C7</i>	c.289A>G	p.Ile97Val	T/D/D	-/Het	3	<p>Clinical features: Chromosome 6p24-26 deletion syndrome, progressive motor difficulties, colobomas, retinal changes, and scoliosis.</p> <p>Investigations: Symmetrical white matter disease, ventriculomegaly. Negative autoantibody screen and no systemic symptoms or other organ involvement. No acute phase response. Negative CSG OGB and normal levels of CSF neopterin.</p> <p>Treatment: corticosteroids and</p>	Unclassified neuroinflammatory disease
				<i>FBN2</i>	C.362A>G	p.Asp121Gly	D/P/D	AD/Het	3		
				<i>NOTCH1</i>	c.4823G>A	p.Arg1608His	T/D/D	AD/Het	3		
				<i>HFE</i>	c.283G>C	p. Asp 95His	D/D/D	AD/AR/Het	3		
				<i>NOD2</i>	c.859C>T	p.His287Tyr	T/P/N	AD/Het	3		
				<i>NOD2</i>	c.2046G>T	p. Leu 682Phe	D/D/D	AD/ Het	3		
				<i>RANBP2</i>	c.6362A>G	p. Gln2121Arg	T/D/D	AD/Het	3		
				<i>RANBP2</i>	c.7172C>G	p. Thr2391Ser	T/B/N	AD/Het	3		
				<i>RARS</i>	c.982G>A	p. Val 328 Ile	T/B/N	AR/Het	3		
				<i>USP18</i>	c.974A>G	p.Asn325Ser	T/B/N	AR/Het	3		

				<i>USP18</i>	c.1115G>T	p.Cys372 Phe	D/B/N	AR/Het	3	mycophenolate mofetil. Required VP shunt for ventriculomegaly.	
44		F	15	<i>MASP2</i>	c.881C>T	p.Thr294 Met	D/B/N	AR/Het	3	Clinical features: Ophthalmoplegia, proptosis, retinal artery occlusion. No systemic symptoms or other organ involvement. Investigations: MRI brain showed widespread leucoencephalopathy. Mitochondrial DNA mutation testing negative. Negative autoantibody screen and no acute phase response. Treatment: Nil	Unclassified neuroinflammatory disease
				<i>PLOD1</i>	c.1534C>T	p.Arg512 Cys	D/D/D	AR/Het	3		
				<i>COPA</i>	c.766G>C	p.Val256 Leu	T/B/D	AD/Het	3		
				<i>PRF1</i>	c.632C>T	p.Ala211 Val	T/B/N	AR/Het	3		
				<i>PLCG2</i>	c.2011A>G	p.Ile671Val	T/B/D	AD/Het	3		
				<i>PRX</i>	c.4376C>T	p.Ala1459Val	D/D/D	AD;AR/Het	3		
				<i>RANBP2</i>	c.3253A>C	p.Lys1085Gln	T/D/D	AD/Het	3		
				<i>SLC2A10</i>	c.674G>A	p.Arg225 His	D/D/N	AR/Het	3		
				<i>USP18</i>	c.974A>G	p.Asn325 Ser	T/B/N	AR/Het	3		
				<i>C2</i>	c.1305T>A	p.His435 Gln	D/D/D	AR/Het	3		
				<i>MEFV</i>	c.442G>C	p.Glu148 Gln	D/D/P	AD;AR/Het	3		
				<i>ELN</i>	c.1492G>A	p.Ala498 Thr	D/D/D	AD/Het	3		
<i>SPTAN1</i>	c.4525G>A	p.Asp1509Asn	T/B/D	AD/Het	3						
45		F	9	<i>PEX14</i>	c.26A>T	p.Gln9Leu	D/B/D	AR/Het	3	Clinical features: HLH, febrile seizures, serositis, enteropathy, hypothyroidism	Likely primary HLH
				<i>CIQC</i>	c.559G>A	p.Val187Ile	T/B/N	AR/Het	3		

			<i>ERCC3</i>	c.1411G>A	p.Val471Ile	D/D/D	AR/Het	3	<p>Investigations: bilateral symmetrical white matter lesions, extensive infection screening negative, primary HLH functional assays negative.</p> <p>Treatment: corticosteroids, anakinra, methotrexate, baricitinib, plasma exchange, IVIG.</p>
			<i>MYLK</i>	c.1182_1184del	p.Val395del	./.	AD/Hom	3	
			<i>CLCN2</i>	c.1859A>T	p.Glu620Val	D/B/D	AD;AR/Het	3	
			<i>C6</i>	c.2800G>A	p.Ala934Thr	T/B/N	-/Het	3	
			<i>C6</i>	c.1848G>A	p.Met616Ile	D/B/N	-/Het	3	
			<i>C6</i>	c.1701G>C	p.Gln567His	T/B/N	-/Het	3	
			<i>NDUFS4</i>	c.373G>T	p.Val125Phe	T/P/N	AR;Mi;XLD/Het	3	
			<i>CSF1R</i>	c.733G>A	p.Ala245Thr	T/B/N	AD/Het	3	
			<i>PARN</i>	c.1741G>A	p.Gly581Arg	T/B/N	AD;AR/Het	3	
			<i>NOD2</i>	c.1411C>T	p.ARG471Cys	T/B/N	AD;Mi/Het	3	
			<i>CTCI</i>	c.370T>G	p.Leu124Val	T/B/N	AR/Het	3	
			<i>STXBP2</i>	c.953C>T	p.Thr318Met	T/D/D	-/Het	3	
			<i>STXBP2</i>	c.1375C>T	p.Arg459Tyr	D/D/N	-/Het	3	
			<i>NOTCH3</i>	c.5764G>T	p.Val1922Leu	T/D/D	AD/Het	3	
			<i>PRX</i>	c.2101G>A	p.Val701M	T/P/N	AD;AR/Het	3	
			<i>CBS;CBSL</i>	c.588G>C	p.Arg196Ser	T/B/D	AR/Het	3	
			<i>USP18</i>	c.974A>G	p.Asn325Ser	T/B/N	AR/Het	3	

46		F	8 months	<i>PSMB9</i>	c.517C>T	p.Arg173 Cys	D/D/D	AR/Het	3	<p>Clinical features: Seizures, developmental delay, Right sided hemiplegia and lethargy, livedo reticularis. No other systemic symptoms or other organ involvement.</p> <p>Investigations: MRI brain showed left sided MCA infarct and widespread white matter disease. Skin biopsy suggested occlusive endotheliopathy. Negative autoantibody screen and no acute phase response.</p> <p>Treatment: corticosteroids and aspirin, mycophenolate mofetil.</p>	Unclassified neuroinflammatory disease
				<i>SKIV2L</i>	c.1705G>A	p.Val569 Met	T/D/D	AR/Het	3		
				<i>RANBP2</i>	c.1258A>G	p.Thr420 Ala	T/B/N	AD/Het	3		
				<i>PEX6</i>	c.235G>C	p.Ala79Pro	T/B/N	AR/Het	3		
				<i>ISG15</i>	c.142C>T	p.His48Tyr	T/B/N	AR/Het	3		
				<i>RNF213</i>	c.12463A>C	p.Thr4155Pro	T/P/N	AR/Het	3		
				<i>PRF1</i>	c.272C>T	p.Ala91 Val	D/D/D	AR/Het	3		
				<i>USP18</i>	c.974A>G	p.Asn325 Ser	T/B/N	AR/Het	3		
47		F	15	<i>C8A</i>	c.1558C>T	p.Arg520 Cys	D/D/N	AR/Het	3	<p>Clinical features: Progressive neurological disorder with no systemic symptoms or other organ involvement.</p> <p>Investigations: MRI brain showed cystic encephalomalacia affecting left frontal lobe, right occipital lobe and right temporal lobe. Meningeal biopsy showed</p>	Unclassified neuroinflammatory disease
				<i>ELN</i>	c.1363G>A	p.Ala455 Thr	././N	AD/Het	3		
				<i>GATA2</i>	c.481C>G	p.Pro161 Ala	T/D/D	AD/Het	3		
				<i>NOD2</i>	c.1292C>T	p.Ser431 Leu	D/P/N	AD/Het	3		
				<i>NOD2</i>	c.1390G>A	p.Gly464Arg	T/P/N	AD/Het	3		
				<i>NOD2</i>	c.2377G>A	p.Val793 Met	D/P/D	AD/Het	3		

				<i>PEX26</i>	c.911G>A	p.Arg304His	T/B/N	AR/Het	3	lymphocytic infiltrate and reactive gliosis. Autoantibodies negative. Negative CSF OGB. Treatment: corticosteroids, mycophenolate mofetil.	
				<i>PHYH</i>	c.238C>T	p.Arg80Cys	T/B/D	AR/Het	3		
				<i>RNASE T2</i>	c.643G>A	p.Glu215Lys	T/D/N	AR/Het	3		
				<i>TSC2</i>	c.3140T>C	p.Val1047Ala	T/B/D	AD/Het	3		
				<i>TUFM</i>	c.760G>A	p.Ala254Thr	T/B/N	AR/Het	3		
				<i>USP18</i>	c.974A>G	p.Asn325Ser	T/B/N	AR/Het	3		
				<i>WDR1</i>	c.512C>T	p.Ala171Val	T/B/D	-/Het	3		
48		F	14	<i>ATP7B</i>	c.442C>T	p.Arg148Trp	D/D/D	AR/Het	3	Clinical features: Spasticity, dystonia, sensory neuropathy, severe myopia and astigmatism, episode of right sided hemiparesis and collapse. No systemic symptoms or other organ involvement. Investigations: MRI/MRA brain showed subacute right intraventricular haemorrhage and a left MCA infarct with involvement of the basal ganglia associated with cerebral oedema. MRA showed irregular narrowing of the left ICA and distal basilar	Unclassified neuroinflammatory disease
				<i>C7</i>	c.1606G>A	p.Val536Ile	T/B/N	-/Het	3		
				<i>COL4A1</i>	c.1673C>T	p.Ala558Val	T/B/D	AD/Het	3		
				<i>FBNI</i>	c.5865G>T	p.Gln1955His	T/B/D	AD/Het	3		
				<i>HEPACAM</i>	c.139G>A	p.Val47Met	T/D/D	AR/Het	3		
				<i>LPIN2</i>	c.1876C>T	p.Pro626Ser	T/B/N	-/Het	3		
				<i>NDUFS2</i>	c.1234G>C	p.Val412Leu	D/B/D	AR/Het	3		
				<i>USP18</i>	c.974A>G	p.Asn325Ser	T/B/N	AR/Het	3		

											artery. Negative CSF OGB and normal CSF neopterins. Negative autoantibody screen and no acute phase response. Treatment: corticosteroids	
49		M	8	<i>ATP7B</i>	c.4175T>C	p.Met139 2Thr	T/B/D	AR/Het	3	Clinical features: Severe bilateral optic atrophy and visual impairment, bulbar palsy, hearing loss. No systemic symptoms or other organ involvement. Investigations: MRI brain showed extensive dural thickening most prominently along the right frontal convexity with cavernous sinus involvement and narrowing of the left ICA, signal abnormality associated with extensive dural enhancement along the left cerebellar hemisphere and obliteration of the left sigmoid sinus where it drains into the internal jugular vein on the left, consistent with jugular vein thrombosis.	Likely STA-4 deficiency, novel disease on-going functional experiments	
				<i>C5</i>	c.4133A>T	p.Tyr137 8Phe	T/B/N	AD/Het	3			
				<i>C6</i>	c.11G>T	p.Arg4Leu	T/B/N	-/Het	3			
				<i>CBL</i>	c.105_106ins CAC	p.His42_ L43insHis	././	AD;Smu/Hom	3			
				<i>CBS</i>	c.1273G>A	p.Val425 Met	D/D/D	AR/Het	3			
				<i>CFHR5</i>	c.427A>C	p.Thr143 Pro	T/P/N	AD/Het	3			
				<i>COL3A1</i>	c.130G>A	p.Val 44Ile	T/D/D	AD/Het	3			
				<i>COQ8A</i>	c.1876C>T	p.Arg626 Cys	T/B/N	AR/Het	3			
				<i>COX10</i>	c.773T>A	p.Leu 258His	D/D/D	AR; MI/Het	3			
				<i>CSF1R</i>	c.721A>G	p.N241 Asp	T/B/N	AD/Het	3			
				<i>CYP27A1</i>	c.506C>T	p.Ala 169Val	T/P/N	AR/Het	3			
				<i>ELN</i>	c.931G>A	p.Ala311 Thr	D/D/D	AD/Het	3			
	<i>FBN2</i>	c.4784C>T	p.Thr159 5Ile	T/B/N	AD/Het	3						

				<i>FOXP3</i>	c.171_173del	p.Ser60del	./.	AR;XLR/Hom	3	Necrotising granulomatous inflammation on brain biopsy. Negative autoantibodies. normal ACE, no infection identified (including TB and atypical TB). Treatment: anti TB medication, corticosteroids and azathioprine.
				<i>ITPR3</i>	c.1588G>C	p.Gly530Arg	T/D/D	AR/Het	3	
				<i>NOTCH1</i>	c.6454G>C	p.Gly2152Arg	T/B/	AD/Het	3	
				<i>PEX1</i>	c.1142C>A	p.Ala381Asp	D/B/N	AR/Het	3	
				<i>PHYH</i>	c.568G>A	p.Val190Ile	T/D/D	AR/Het	3	
				<i>POLG</i>	c.158_159insGCA	p.Gln55_P56insGln	./.	AD;AR/Het	3	
				<i>RNF213</i>	c.103G>A	p.Glu35Lys	T/B/N	-/Het	3	
				<i>SLC29A3</i>	c.74G>A	p.Arg25Gln	T/B/N	AR/Het	3	
				<i>STAT4</i>	Exon 4 Deletion	-	-	-/Hom	-	
				<i>TMEM173</i>	c.659G>A	p.Arg220His	T/B/N	AD/Het	3	
				<i>TSC2</i>	c.4316G>A	p.Gly1439Asp	T/P/N	AD/Het	3	
				<i>TTC37</i>	c.4414A>G	p.Thr1472Ala	T/B/N	AR/Het	3	
				<i>UNC13D</i>	c.740T>G	p.Val247Gly	D/D/D	-/Het	3	
				<i>USP18</i>	c.974A>G	p.Asn325Ser	T/B/N	AR/Het	3	
				<i>USP18</i>	c.1089T>A	p.Tyr363Xaa	./D	AR/Het	3	
50		M	14	<i>ADAR</i>	c.1577A>G	p.Gln526Arg	D/D/D	AD;AR/Het	3	Clinical features: Systemic lupus

				<i>CTCI</i>	c.1795C>T	p.Pro599 Ser	T/B/N	AR/Het	3	erythematous disease with skin rashes, arthralgia. Investigations: positive ANA and dsDNA antibodies, with worsening leucoencephalopathy on MRI brain imaging, but no intracerebral calcification. Treatment: corticosteroids, cyclophosphamide and rituximab.	Likely systemic lupus erythematous
				<i>MASP2</i>	c.1351G>A	p.Ala451 Thr	T/B/P	AR/Het	3		
				<i>MFN2</i>	c.439C>A	p.Leu147I le	T/B/D	AD;AR/Het	3		
				<i>MYLK</i>	c.1007C>T	p.Pro336 Leu	D/P/N	AD/Het	3		
				<i>PSTPIP 1</i>	c.203C>T	p.Thr68Met	T/P/D	AD/Het	3		
				<i>RANBP 2</i>	c.2339C>T	p.Pro780 Leu	D/B/D	AD/Het	3		
				<i>RANBP 2</i>	c.6362A>G	p.Gln2121 Arg	T/D/D	AD/Het	3		
				<i>RNF213</i>	c.15017C>T	p.Ser5006 Leu	T/B/N	-/Het	3		
				<i>TGFBR 2</i>	c.374delA	p.Lys128 Serfs*34	././	AD/Hom	3		
				<i>UNC13 D</i>	c.2782C>T	p.Arg928 Cys	T/B/N	-/Het	3		
51		F	10	<i>C5</i>	c.512T>C	p.Val171 Ala	D/D/D	AD/Het	3	Clinical features: Acute onset hemiplegia and encephalopathy. No systemic symptoms or other organ involvement. Investigations: MRI/MRA showed bilateral multifocal vasculopathy. Negative autoantibody screen and no acute phase	Unclassified neuroinflammatory disease
				<i>C7</i>	c.1258A>C	p.Lys420 Gln	D/D/D	-/Het	3		
				<i>C8B</i>	c.1625C>T	p.Thr542I le	T/B/N	AR/Het	3		
				<i>CBS</i>	c.518T>C	p.Ile173Thr	D/D/A	AR/Het	4		
				<i>CLEC16 A</i>	c.2728G>A	p.Gly910 Ser	T/P/D	-/Het	3		
				<i>EIF2B3</i>	c.407A>G	p.Gln136 Arg	T/B/N	AR/Het	3		

				<i>ELN</i>	c.328A>g	p.Ala110 Thr	D/D/D	AD/Het	3	response. Negative CSF OGB. Treatment: Corticosteroids, IVIG	
				<i>GJC2</i>	c.1067A>G	p.Gln356 Arg	T/B/N	AD;AR/Het	3		
				<i>RANBP2</i>	c.7754T>C	p.Ile2585 Thr	T/B/N	AD/Het	3		
				<i>RNF213</i>	c.6551A>G	p.Gln218 4Arg	T/B/N	AD/Het	3		
				<i>TGFBR2</i>	c.374delA	p.Lys128 Serfs*34	./.	AD/Hom	3		
				<i>TSC2</i>	c.856A>G	p.Met286 Val	T/B/N	AD/Het	3		
				<i>USP18</i>	c.295G>A	p.Val99Ile	T/D/N	AR/Het	3		
				<i>USP18</i>	c.974A>G	p.Asn325 Ser	T/B/N	AR/Het	3		
				<i>USP18</i>	c.1115G>T	p.Cys372 Phe	D/B/N	AR/Het	3		
				<i>GLA</i>	c.61C>T	p.Leu21Phe	T/B/N	XL/Het	3		
52		M	3	<i>AARS2</i>	c.1661G>A	p.Arg554 His	T/B/D	AR/Het	3	Clinical features: Encephalopathy Investigations: MRI brain suggestive of diffuse necrotising encephalopathy clinical presentation. No systemic symptoms or other organ involvement. Positive ANA and ACL antibodies at presentation subsequently negative when tested 12 weeks later.	Unclassified neuroinflammatory disease
				<i>EIF2B3</i>	c.1025C>T	p.Ser342 Leu	T/B/N	AR/Het	3		
				<i>LPIN2</i>	c.755C>T	p.Ala252 Val	T/B/N	-/Het	3		
				<i>MEFV</i>	c.442G>C	p.Glu148 Gln	D/D/P	AD;AR/Het	3		
				<i>SLC25A12</i>	c.995T>G	p.Leu332 Arg	D/D/D	AR/Het	3		

											Treatment: corticosteroids and IVIG.	
53		F	2	<i>C2</i>	c.839_849del	p.Met280 Asnfs*3	./.	AR/Het	3	Clinical features: Fever, maculopapular rash, encephalopathy, anaemia, lymphadenopathy, hepatosplenomegaly. Investigations: MRI brain showed diffuse oedema. Positive CSF OGB. Negative autoantibodies and extensive infection screen negative. Treatment: corticosteroids, IVIG, plasma exchange.	Unclassified neuroinflammatory disease	
				<i>C5</i>	c.2653C>T	p.Arg885 Cys	T/P/N	AD/Het	3			
				<i>C5</i>	c.1060C>A	p. Leu 354Met	D/D/D	AD/Het	3			
				<i>CYP27A1</i>	c.536A>G	p.Asn179 Ser	D/P/D	AR/Het	3			
				<i>CYP27A1</i>	c.1151C>T	p.Pro384 Leu	D/D/D	AR/Het	3			
				<i>NDUFA1</i>	c.199G>A	p.Val67Ile	D/B/N	AR/Het	3			
				<i>PEX10</i>	c.880A>G	p.Thr294 Ala	T/D/D	AR/Het	3			
				<i>PEX2</i>	c.748T>C	p.Trp250 Arg	T/D/D	AR/Het	3			
				<i>PYCR2</i>	c.898C>G	p.Leu300 Val	D/B/N	AR/Het	3			
				<i>SAMD3</i>	c.1378G>A	p.Asp460 Asn	T/D/D	-/Het	3			
				<i>SLCIA4</i>	c.40G>A	p.Ala14Tj r	T/B/D	AR/Het	3			
				<i>STAT2</i>	c.2478G>T	p.Gln826 His	D/B/N	AR/Het	3			
				<i>TRAP1</i>	c.1432_1433 insCCG	p.Ser477_ Gly 478insAla	./.	-/Het	3			
	<i>TRAP1</i>	c.1429T>G	p.Ser477 Ala	T/B/N	-/Het	3						
	<i>UNC13D</i>	c.2782C>T	p.Arg928 Cys	T/B/N	-/Het	3						

				<i>USP18</i>	c.974A>G	p.Asn325 Ser	T/B/N	AR/Het	3		
54		M	11	<i>C8B</i>	c.444C>G	p.Asp148 Glu	D/D/D	AR/Het	3	<p>Clinical features: Febrile induced epilepsy refractory to treatment.</p> <p>Investigations: MRI brain showed symmetrical contrast enhancing basal ganglia and external capsule, cerebral cortex and frontal lobe lesions associated with brain atrophy. Normal spinal appearances. Extensive metabolic, infectious disease and rheumatological causes excluded.</p> <p>Treatment: Corticosteroids</p>	Unclassified neuroinflammatory disease
				<i>RANBP2</i>	c.6362A>G	p.Gln212 1Arg	T/D/D	AD/Het	3		
				<i>C6</i>	c.1355G>A	p. Gly 452Glu	D/B/N	-/Het	3		
				<i>C6</i>	c.10C>T	p.Arg4Cys	T/B/N	-/Het	3		
				<i>PEX1</i>	c.1579A>G	p. Thr527 Ala	T/B/D	AR/Het	3		
				<i>PEX2</i>	c.748T>C	p. Trp250 Arg	T/D/D	AR/Het	3		
				<i>TRAP1</i>	c.598A>G / c.757A>G	p. Ile200Val / Ile253Val	T/B/D	-/Het	3		
				<i>PEX26</i>	c.457C>G	p. Leu153 Val	T/B/N	AR/Het	3		
55		F	7	<i>EIF2B4</i>	c.913C>G	p. Arg305 Gly	T/B/N	AR/Het	3	<p>Clinical features: Spasticity, dystonia, bulbar symptoms with dysphagia, speech regression, microcephaly. No systemic symptoms or other organ involvement.</p> <p>Investigations: MRI brain showed lack of myelin maturation in frontal lobes, no leukodystrophy. Negative autoantibody screen and no systemic</p>	Unclassified neuroinflammatory disease
				<i>NLRC4</i>	c.2785G>T	p. Ala929 Ser	T/B/.	AD/Het	3		
				<i>COL3A1</i>	c.505C>T	p. Leu169 Phe	T/B/N	AD/Het	3		
				<i>CFI</i>	c.1322A>G	p. Lys441 Arg	T/B/N	AD;AR/Het	3		
				<i>ETFDH</i>	c.572G>A	p. Gly191 Asp	D/P/D	AR/Het	3		
				<i>OTULIN</i>	c.345G>T	p. Gln115 His	T/B/D	AR/Het	3		
				<i>C2</i>	c.1922T>C	p. Val641 Ala	T/B/N	AR/Het	3		

				<i>SPTAN1</i>	c.3803T>C	p.Val126 8Ala	D/D/D	AR/Het	3	symptoms or other organ involvement. Treatment: IVIG.	
				<i>MEFV</i>	c.1222C>T	p.Arg408 Trp	T/B/N	AD;AR/Het	3		
				<i>ALDH3 A2</i>	c.1270C>T	p.Pro424 Ser	T/B/D	AR/Het	3		
				<i>GFAP</i>	c.1288C>T	p.Arg430 Cys	D/B/D	AD/Het	3		
				<i>USP18</i>	c.1115G>T	p.Cys372 Phe	D/B/N	AR/Het	3		
56		M	11	<i>EIF2B5</i>	c.1202G>A	p.Arg401 Gln	T/B/N	AR/Het	3	Clinical features: Encephalopathy, seizures, cognitive dysfunction. No systemic symptoms or other organ involvement. Investigations: MRI brain showed diffuse cortical blurring with symmetrical signal abnormality in the claustra adjacent to the external capsules and the juxtacortical white matter of the right temporal lobe. No spinal pathology. Negative autoantibody profile and no acute phase response. Treatment: corticosteroids and IVIG.	Unclassified neuroinflammatory disease
				<i>CLCN2</i>	c.218G>A	p.Arg73H is	T/B/D	AD;AR/Het	3		
				<i>TTC37</i>	c.3808C>G	p.Pro1270 Ala	T/B/D	AR/Het	3		
				<i>RARS</i>	c.982G>A	p.Val328I le	T/B/N	AR/Het	3		
				<i>GALC</i>	c.17A>G	p.His6Ar g	D/B/N	AR/Het	3		
				<i>NDUFA F1</i>	c.215C>G	p.Thr72S er	T/B/N	AR/Het	3		
				<i>RNF213</i>	c.14999A>G	p.Gln500 0Arg	D/D/D	-/Het	3		
				<i>USP18</i>	c.295G>A	p.Val99I e	T/P/N	AR/Het	3		
				<i>MEFV</i>	c.442G>C	p.Glu148 Gln	D/D/P	AD;AR/Het	3		
				<i>ARSA</i>	c.*96A>G	-	././	AR/Het	3		
				<i>ARSA</i>	c.1055A>G	p.Asn352 Ser	T/B/P	AR/Het	3		
57		F	13	<i>LYST</i>	c.8913T>G	p.Asn297 1Lys	T/P/D	AR/Het	3	Clinical features: Isolated episode of	

				<i>LYST</i>	c.5518T>G	p.Ser1840 Ala	T/B/D	AR/Het	3	hemiplegia and ataxia. No systemic symptoms or other organ involvement. Investigations: MRI brain showed multiple white matter lesions in both hemispheres, posterior fossa, spinal cord with contrast enhancement and optic nerve swelling. Negative autoantibody profile and no acute phase response. Treatment: Nil	Unclassified neuroinflammatory disease
				<i>FBN2</i>	c.68C>G	p.Ala23Gly	D/B/N	AD/Het	3		
				<i>ELN</i>	c.259T>C	p.Phr87Leu	D/B/N	AD/Het	3		
				<i>PEX2</i>	c.748T>C	p.Trp250Arg	T/D/D	AR/Het	3		
				<i>SPTAN1</i>	c.965A>C	p.Gln322Pro	T/P/D	AD/Het	3		
				<i>CLEC16A</i>	c.1024C>G	p.Leu342Val	T/D/D	-/Het	3		
				<i>PLCG2</i>	c.2393A>G	p.Asn798Ser	D/D/D	AD/Het	3		
				<i>NF1</i>	c.2342A>T	p.His781Leu	T/B/D	AD/Het	3		
				<i>LONP1</i>	c.2485G>A	p.Ala829Thr	T/B/N	AR/Het	3		
				<i>CBS;CBSL</i>	c.833T>C	p.Ile278Thr	D/P/A	AR/Het	4		
58		F	8	<i>PLOD1</i>	c.607C>A	p.Arg203Ser	D/B/D	AR/Het	3	Clinical features: Microcephaly, seizure disorder. No systemic symptoms or other organ involvement. Investigations: MRI brain showed leukodystrophy and intracerebral calcification. Negative autoantibody profile and no acute phase response.	Unclassified neuroinflammatory disease
				<i>CFH</i>	c.737G>C	p.Arg246Thr	T/D/D	AD;AR/Het	3		
				<i>CFHR5</i>	c.329T>C	p.Val110Ala	D/P/N	AD/Het	3		
				<i>COQ8A</i>	c.25A>G	p.Ile9Val	D/B/D	AR/Het	3		
				<i>LYST</i>	c.8497G>A	p.Ala2833Thr	D/B/N	AR/Het	3		
				<i>GFMI</i>	c.77A>G	p.Lys26Arg	T/B/D	AR/Het	3		
				<i>TMEM173</i>	c.1124G>T	p.Arg375Leu	D/D/D	AD/Het	3		

				<i>EIF2B2</i>	c.982A>G	p.Ile328Val	T/B/D	AR/Het	3	Treatment: Corticosteroids	
				<i>FBN1</i>	c.4277G>C	p.Gly1426Ala	T/D/D	AD/Het	3		
				<i>MEFV</i>	c.442G>C	p.Glu148Gln	D/D/P	AD;AR/Het	3		
				<i>PSTPIP1</i>	c.1115C>T	p.Ala372Val	D/D/D	AD/Het	3		
				<i>TSC2</i>	c.2348C>G	p.Thr783Ser	T/B/N	AD/Het	3		
59		M	1	<i>CFHR5</i>	c.1067G>A	p.Arg356His	T/P/N	AD/Het	3	Clinical features: Seizure disorder. No systemic symptoms or other organ involvement. Investigations: Intracerebral calcification on CT brain. Negative autoantibody profile and no acute phase response. Treatment: Nil	Unclassified neuroinflammatory disease
				<i>CFHR5</i>	c.1412G>A	p.Gly471Glu	D/P/N	AD/Het	3		
				<i>TGFBR2</i>	c.374del	p.Lys128Serfs*34	./.	AD/Het	3		
				<i>NOTCH1</i>	c.4372G>A	p.Ala1458Thr	D/B/N	AD/Het	3		
				<i>MVK</i>	c.877G>A	p.Val293Met	T/P/N	AD;AR/Het	3		
				<i>PEX12</i>	c.785_787del	p.Asp262_Trp263delinsG	./.	AR/Het	3		
				<i>RNF213</i>	c.11882A>G	p.Glu3961Gly	T/B/N	-/Het	3		
				<i>PRX</i>	c.731C>T	p.Ala244Val	T/B/N	AD;AR/Het	3		
60		M	10	<i>YYIAP1</i>	c.320G>A	p.Gly107Glu	D/B/D	AR/Het	3	Clinical features: Left sided hemiplegia and progressive motor function deterioration, ataxia.	Unclassified neuroinflammatory disease
				<i>CFHR5</i>	c.1067G>A	p.Arg356His	T/P/N	AD/Het	3		
				<i>LYST</i>	c.8806G>A	p.Val2936Ile	T/B/D	AR/Het	3		

				<i>IFIH1</i>	c.2138C>G	p.Thr713 Ser	T/B/D	AD/Het	3	<p>Investigations: MRI brain showed diffuse predominantly white matter diseases in right frontal lobe involving the ipsilateral deep grey matter and extending into the right cerebral peduncle.</p> <p>Brain biopsy suggestive of perivascular inflammatory process predominantly lymphocytic. Negative autoantibody profile.</p> <p>Treatment: corticosteroids, cyclophosphamide and mycophenolate mofetil.</p>	
				<i>TSC1</i>	c.2194C>T	p.His732 Tyr	D/P/A	AD/Het	3		
				<i>NOTCH1</i>	c.4129C>T	p.Pro1377 Ser	T/B/N	AD/Het	3		
				<i>COL4A1</i>	c.161C>T	p.Pro54L eu	D/D/D	AD/Het	3		
				<i>RNF213</i>	c.5114C>A	p.Thr170 5Lys	D/.D	-/Het	3		
				<i>RNF213</i>	c.9952A>G	p.Ile3318 Val	T/B/N	-/Het	3		
				<i>PRX</i>	c.1483G>C	p.Glu495 Gln	T/B/D	AD;AR/Het	3		
61		F	6	<i>LYST</i>	c.5518T>G	p.Ser1840 Ala	T/B/D	AR/Het	3	<p>Clinical features: Bilateral optic atrophy with severe visual loss, oral ulceration, arthralgia, fatigue. No systemic symptoms or other organ involvement</p> <p>Investigations: Negative autoantibody profile. Normal complement studies.</p> <p>Treatment: corticosteroids.</p>	Unclassified neuroinflammatory disease
				<i>RANBP2</i>	c.7172C>G	p.Thr239 1Ser	T/B/N	AD/Het	3		
				<i>COL3A1</i>	c.1165A>T	p.Asn389 Tyr	D/B/N	AD/Het	3		
				<i>GFMI</i>	c.490C>T	p.Arg164 Cys	D/D/D	AR/Het	3		
				<i>C6</i>	c.2087A>G	p.Asp696 Gly	T/B/D	-/Het	3		
				<i>C2</i>	c.39_849del	p.Met280 Asnfs*3	././	AR/Het	3		
				<i>PSMB8</i>	c.689A>G	p.Tyr230 Cys	D/B/D	AR/Het	3		

				<i>POLG</i>	c.158_159ins GCA	p.Gln55_ Pro56ins Gln	././.	AD;AR/Het	3		
				<i>MYH11</i>	c.5275G>A	p.Val175 9Ile	T/B/N	AD/Het	3		
				<i>RNF213</i>	c.2122C>G	p.His708 Asp	T/B/N	-/Het	3		
				<i>RNF213</i>	c.14194A>G	p.Lys473 2Glu	T/B/N	-/Het	3		
				<i>USP18</i>	c.974A>G	p.Asn325 Ser	T/B/N	AR/Het	3		
62		F	14	<i>LMNA</i>	c.1672G>A	p.Gly558 Arg	D/P/D	AD;AR/Het	3	Clinical features: Retinitis. No systemic symptoms or other organ involvement. Investigations: MRI brain showed leucoencephalopathy. Negative autoantibody profile and no acute phase response. Treatment: Nil	Unclassified neuroinflammatory disease
			<i>CYP27A1</i>	c.1151C>T	p.Pro384 Leu	D/D/D	AR/Het	3			
			<i>AARS2</i>	c.967G>A	p.Val323 Met	D/D/D	AR/Het	3			
			<i>POLG</i>	c.156_158del	p. Gln55del	././.	AD;AR/Hom	3			
			<i>MEFV</i>	c.910G>A	p. Gly 304Arg	D/B/N	AD;AR/Het	3			
			<i>TRAP1</i>	c.109C>T	p.Arg37T rp	T/B/N	- /Het	3			
63		F	15	<i>RANBP2</i>	c.6680A>G	p.Tyr222 7Cys	D/D/D	AD/Het	3	Clinical features: Relapsing-remitting MS like disorder characterised by seizures associated with autistic spectrum disorder and significant developmental delay. Investigations: MRI brain showed multiple, supratentorial white	Multiple sclerosis
			<i>SUMF1</i>	c.95C>T	p.Ala32 Val	T/P/N	AR/Het	3			
			<i>PSMB8</i>	c.208A>T	p.Thr70S er	D/D/D	AR/Het	3			
			<i>ITPR3</i>	c.3489G>C	p.Glu116 3Asp	T/B/D	AR/Het	3			
			<i>PEX7</i>	c.695G>A	p.Arg232 Gln	D/P/D/	AR/Het	3			

				<i>ELN</i>	c.1831G>A	p.Gly611 Arg	T/B/D	AD/Het	3	matter lesions mostly in periventricular/callosal location with other foci of abnormality in the deep and subcortical white matter. Negative autoantibody profile. Normal biotinidase, negative autoantibodies including Aq4/MOG. Positive OGB Treatment: corticosteroids, rituximab, IVIG	
				<i>COL4A1</i>	c.1673C>T	p.Ala558Val	./.	AD/Het	3		
				<i>POLG</i>	c.158_159ins GCA	p.Glyln55_Pro56ins Gln	./.	AD;AR/Het	3		
				<i>TRAP1</i>	c.1432_1433 insCCG	Ser477_Gly478insAla	T/B/N	AR/Het	3		
				<i>RNF213</i>	c.9952A>G	p.Ile3318 Val	T/P/D	AD/Het	3		
				<i>LPIN2</i>	c.1159A>G	p.Lys387 Glu	T/P/D	-/Het	3		
				<i>ERCC2</i>	c.1426G>A	p.Val476Ile	D/B/D	AR/Het	3		
				<i>USP18</i>	c.280G>A	p.Glu94Lys	D/D/N	AR/Het	3		
64		F	18m onths	<i>MASP2</i>	c.467G>A	p.Cys156 Tyr	D/D/D	AR/Het	3	Clinical features: Sensorineural hearing loss, cardiomyopathy, hepatosplenomegaly, squint, hypotonia. Investigations: MRI brain showed posterior fossa haemorrhage and marked atrophy, distortion of cerebellum and abnormal brainstem. Periventricular calcification. Negative autoantibody profile and no systemic symptoms or other organ involvement.	Unclassified neuroinflammatory disease
				<i>C8A</i>	c.1331G>A	p.Arg444 His	D/D/D	AR/Het	3		
				<i>DGUOK</i>	c.4G>T	p.Ala2Ser	T/B/N	AR/Het	3		
				<i>SLC25A12</i>	c.870G>C	p.Glu290 Asp	T/B/D	AR/Het	3		
				<i>GATA2</i>	c.481C>G	p.Pro161 Ala	T/D/D	AD/Het	3		
				<i>CLCN2</i>	c.704G>A	p.Arg235 Gln	D/D/D	AD;AR/Het	3		
				<i>C6</i>	c.650T>C	p.Ile217Thr	T/B/N	AD/Het	3		
				<i>CLEC16A</i>	c.2707G>A	p. Ala903Thr	D/B/N	-/Het	3		

				<i>GFAP</i>	c.1288C>T	p.Arg430 Cys	D/P/D	AD/Het	3	Treatment: Corticosteroids	
				<i>PRX</i>	c.1490C?T	p.Pro497 Leu	D/B/D	AD;AR/Het	3		
				<i>PRX</i>	c.1483G>C	p.Glu495 Gln	T/B/D	AD;AR/Het	3		
				<i>CBS;CB SL</i>	c.833T>C	p.Ile278T hr	D/D/A	AR/Het	4		
				<i>USP18</i>	c.974A>G	p.Asn325 Ser	T/B/N	AR/Het	3		
65		M	15	<i>PEX10</i>	c.820A>G	p.Thr274 Ala	T/D/D	AR/Het	3	Clinical features: Recurrent fevers, developmental regression, and family history of lupus. Investigations: MRI brain showed white matter disease. Negative autoantibodies and no acute phase response. Treatment: Corticosteroids	Unclassified neuroinflamma tory disease
				<i>MASP2</i>	c.1142C>T	p.Thr381I le	D/D/D	AR/Het	3		
				<i>C8A</i>	c.1723C>T	p.Pro575 Ser	T/B/N	AR/Het	3		
				<i>RANBP 2</i>	c.6362A>G	p.Gln212 1Arg	T/D/D	AD/Het	3		
				<i>IFIH1</i>	c.2767A>G	p.Ile923V al	T/D/D	AD/Het	3		
				<i>GBE1</i>	c.2017G>A	p.Ala673 Thr	T/B/N	AR/Het	3		
				<i>WDR1</i>	c.743A>G	p.His248 Arg	T/B/D	-/Het	3		
				<i>NOTCH 1</i>	c.3836G>A	p.Arg127 9His	T/B/D	AD/Het	3		
				<i>NOTCH 1</i>	c.2542G>A	p.Glu848 Lys	T/D/D	AD/Het	3		
				<i>TSC2</i>	c.1100G>A	p.Arg367 Gln	T/D/D	AD/Het	3		
				<i>MEFV</i>	c.554G>T	p.Gly185 Val	T/P/N	AD;AR/Het	3		
				<i>MEFV</i>	c.537C>G	p.Ser179 Arg	D/P/N	AD;AR/Het	3		

				<i>TRAP1</i>	c.1324G>A	p.Glu442 Lys	T/B/D	-/Het	3		
				<i>CTCI</i>	c.2162G>C	p.Gly 721 Ala	T/B/N	AR/Het	3		
				<i>CTCI</i>	c.1241G>C	p.Gly414 Ala	T/D/D	AR/Het	3		
				<i>USP18</i>	c.295G>A	p.Val99I e	T/D/N	AR/Het	3		
				<i>USP18</i>	c.974A>G	p.Asn325 Ser	T/B/N	AR/Het	3		
66		M	10	<i>COL3A1</i>	c.4165G>T	p.Ala138 9Ser	T/B/N	AD/Het	3	Clinical features: Common variable immunodeficiency, PANDAS like syndrome, colitis. Investigations: MRI brain non-specific white matter disease. Negative autoantibody profile. Treatment: IVIG	Unclassified neuroinflammatory disease
				<i>DDX58</i>	c.212G>A	p.Arg71H is	D/D/N	AD/Het	3		
				<i>CBL</i>	c.2588A>G	p.Asn863 Ser	T/B/N	AD;Smu/Het	3		
				<i>NOD2</i>	c.3017dupC	p.Leu100 7Profs*1	././	AD;Mu/Hom	3		
				<i>POLG2</i>	c.1247G>C	p.Gly416 Ala	T/D/D	AD/Het	3		
				<i>LPIN2</i>	c.1654C>G	p.Pro552 Ala	D/D/D	-/Het	3		
				<i>PRX</i>	c.1483G>C	p.Glu495 Gln	T/B/N	AD;AR/Het	3		
67		M	15	<i>RANBP2</i>	c.6680A>G	p.Tyr222 7Cys	D/D/D	AD/Hom	3	Clinical features: Common variable immunodeficiency, PANDAS like syndrome, colitis. MRI brain non-specific white matter disease. Negative autoantibody profile. Treatment: IVIG	Unclassified – neuroinflammatory disease
				<i>FBN2</i>	c.4312G>A	p.Glu143 8Lys	T/P/D	AD/Het	3		
				<i>ITPR3</i>	c.4366G>A	p.Glu145 6Lys	T/P/D	AR/Het	3		
				<i>ITPR3</i>	c.7301C>T	p.Ser2434 Leu	T/B/N	AR/Het	3		
				<i>DDX58</i>	c.212G>A	p.Arg71H is	D/D/D	AD/Het	3		

				<i>C5</i>	c.3047C>T	p.Ala101 6Val	T/D/D	AD/Het	3		
				<i>CBL</i>	c.2588A>G	p.Asn863 Ser	T/B/N	AD/Het	3		
				<i>NOD2</i>	c.866A>G	p.Asn289 Ser	T/B/D	AD/Het	3		
				<i>POLG2</i>	c.1247G>C	p.Gly416 Ala	T/D/D	AD/Het	3		
				<i>LPIN2</i>	c.1654C>G	p.Pro552 Ala	D/D/D	-/Het	3		
68		F	18	<i>PEX10</i>	c.820A>G	p.Thr274 Ala	T/D/D	AR/Het	3	<p>Clinical features: Thyroiditis, leucoencephalopathy, peripheral neuropathy, thrombocytopenia. Investigations: MRI brain non progressive white matter disease. Thyroid antibodies positive, other autoantibodies negative Treatment: corticosteroids.</p>	Unclassified neuroinflamma tory disease
				<i>GJC2</i>	c.355G>C	p.Gly119 Arg	T/P/N	AD;AR/Het	3		
				<i>GATA2</i>	c.439C>T	p.Pro147 Ser	D/P/D	AD/Het	3		
				<i>GUCY1 A3</i>	c.720C>G	p.Phe240 Leu	T/B/N	AR/Het	3		
				<i>OTULI N</i>	c.439C>T	p.Pro147 Ser	T/B/N	AR/Het	3		
				<i>HSD17 B4</i>	c.1192T>C	p.Ser398P ro	T/B/N	AR/Het	3		
				<i>LMNB1</i>	c.872C>T	p.Ala291 Val	D/B/D	AD/Het	3		
				<i>PEX6</i>	c.235G>C	p.Ala79Pr o	T/B/N	AD;AR/Het	3		
				<i>NOTCH 1</i>	c.4129C>T	p.Pro1377 Ser	T/B/N	AD/Het	3		
				<i>ERCC6</i>	c.3965G>T	p.Gly132 2Val	D/D/.	AD;AR/Het	3		
				<i>STAT2</i>	c.2473G>T	p. Gly 825C	T/B/N	AR/Het	3		
				<i>TSC2</i>	c.3100G>A	p.Val103 4Ile	D/D/D	AD/Het	3		

				<i>MEFV</i>	c.688G>A	p.E230K	D/B/N	AD;AR/Het	3		
				<i>PLCG2</i>	c.1258G>A	p.Ala420 Thr	T/B/N	AD/Het	3		
				<i>NOTCH3</i>	c.4036C>T	p.His1346 Tyr	T/D/.	AD/Het	3		
69		M	8	<i>MFN2</i>	c.1574A>G	p.Asn525 Ser	T/B/N	AD;AR/Het	3	Clinical features: Autism and epilepsy. No systemic symptoms or other organ involvement Investigations: MRI brain showed non progressive white matter disease. Negative autoantibody profile. Treatment: Nil	Unclassified neuroinflammatory disease
				<i>CIQC</i>	c.8T>C	p.Val3Ala	T/B/N	AR/Het	3		
				<i>C8A</i>	c.1558C>T	p.Arg520 Cys	D/D/N	AR/Het	3		
				<i>RANBP2</i>	c.1258A>G	p.Thr420 Ala	T/B/N	AD/Het	3		
				<i>RANBP2</i>	c.2306G>A	p.Arg769 Gln	T/B/N	AD/Het	3		
				<i>FBN2</i>	c.3476T>C	p.Ile1159 Thr	D/P/D	AD/Het	3		
				<i>RHOD</i>	c.244C>T	p.Arg82T rp	D/D/D	-/Het	3		
				<i>ATP7B</i>	c.406A>G	p.Arg136 Gly	T/B/N	AR/Het	3		
				<i>TSC2</i>	c.5017G>C	p.Val167 3Leu	D/B/N	AD/Het	3		
				<i>NOD2</i>	c.1621C>T	p.Arg541 Trp	D/D/N	AD;Mu/Het	3		
				<i>DNASE2</i>	c.664G>A	p.Gly222 Arg	D/D/D	-/Het	3		
				<i>NOTCH3</i>	c.5779G>A	p.Ala192 7Thr	T/B/D	AD/Het	3		
				<i>TYMP</i>	c.194G>A	p.Ser65A sn	T/B/N	AR/Het	3		
				<i>MEFV</i>	c.442G>C	p.Glu148 Gln	D/D/P	AD;AR/Het	3		
70		F	6	<i>RANBP2</i>	c.5941T>A	p.Ser1981 Thr	T/B/N	AD/Het	3	Clinical features: Arthralgia and	

				<i>DNASE1L3</i>	c.244G>C	p. Gly82Arg	T/B/N	AR/Het	3	erythematous skin rash, headaches and cognitive decline. Investigations: MRI brain showed white matter disease with T2 progressive enhancing lesions. No acute phase response, MPO antibodies positive on one occasion, negative autoantibody screen since. Sibling of patient 66. Treatment: corticosteroids	Unclassified neuroinflammatory disease
				<i>SAMD3</i>	c.1112C>T	p.Thr371Ile	T/P/D	-/Het	3		
				<i>ELN</i>	c.1043G>A	p.Gly348Glu	D/D/D	AD/Het	3		
				<i>STAT2</i>	c.2473G>T	p.Gly825Cys	T/B/N	AR/Het	3		
				<i>POLG</i>	c.158_159insGCA	p.Gln55_Pro56insGln	./.	AD/Het	3		
				<i>HSD17B4</i>	c.1438-2A>G	p.Intronic	./D	AR/Het	3		
71		M	18	<i>RANBP2</i>	c.3162G>T	p. Gln1054His	T/B/D	AD/Het	3	Clinical features: Peripheral neuropathy and erythematous skin rashes. Investigations: MRI brain showed non progressive white matter disease. GAD antibodies positive, remaining autoantibody screen negative. Treatment: corticosteroids	Unclassified neuroinflammatory disease
				<i>RANBP2</i>	c.3163C>T	p.Pro1055Ser	T/B/D	AD/Het	3		
				<i>CLCN2</i>	c.2103G>C	p.Glu701Asp	T/B/N	AD;AR/Het	3		
				<i>CLCN2</i>	c.2012G>A	p.Arg671Gln	T/B/D	AD;AR/Het	3		
				<i>CLCN2</i>	c.1883_1884insCCG	p.Arg629_Gln630insArg	./.	AD;AR/Hom	3		
				<i>ERCC8</i>	c.1012G>A	p. Asp338Asn	T/B/D	AR/Het	3		
				<i>TGFBI</i>	c.1061A>G	p.Asn354Ser	D/P/D	AD/Het	3		
				<i>SAMD3</i>	c.1112C>T	p.T371Ile	T/P/D	-/Het	3		
				<i>ELN</i>	c.1043G>A	p. Gly348Glu	D/D/D	AD/Het	3		

				<i>PEX2</i>	c.748T>C	p.Trp250 Arg	T/D/D	AR/Het	3		
				<i>TBK1</i>	c.1391T>C	p.Val464 Ala	T/B/D	AD/Het	3		
				<i>POLG</i>	c.158_159ins GCA	p.Gln55_Pro56ins Gln	./.	AD;AR/Het	3		
				<i>POLG</i>	c.G125A	p.Arg42Gln	./.	AD;AR/Het	3		
				<i>NOTCH3</i>	c.3399C>A	p.His1133 Gln	T/B/N	AD/Het	3		
				<i>PRX</i>	c.4077_4079 del	p.Glu1361 del	./.	AD;AR/Het	3		
				<i>HSD17B4</i>	c.1438-2A>G	p.Intron1c	./D	AR/Het	3		
72		M	3	<i>CIQC</i>	c.559G>A	p.Val187Ile	T/B/N	AR/Het	3	<p>Clinical features: Episode of HSV encephalitis in infancy treated with antivirals; recurrence of seizures age 4 years old. No other systemic symptoms or other organ involvement</p> <p>Investigations: MRI brain showed widespread asymmetrical cortical and subcortical thalamic enhancing lesions on MRI brain. Brain biopsy revealed granulomatous inflammation. Negative autoantibodies, no acute phase response.</p> <p>Treatment: corticosteroids.</p>	Chronic HSV granulomatous encephalitis
			<i>RANBP2</i>	c.7172C>G	p.Thr2391Ser	T/B/N	AD/Het	3			
			<i>TGFBR2</i>	c.449del	p.Lys153Serfs*34	./.	AD/Het	3			
			<i>PEX1</i>	c.3283G>A	p.Asp1095Asn	T/D/D	AR/Het	3			
			<i>POLG2</i>	c.1105A>G	p.Arg369Gly	D/D/D	AD/Het	3			
			<i>ERCC2</i>	c.442C>T	p.His148Tyr	T/B/D	AR/Het	3			
			<i>NLRP12</i>	c.3088C>G	p.Arg1030Gly	D/D/N	AD/Het	3			

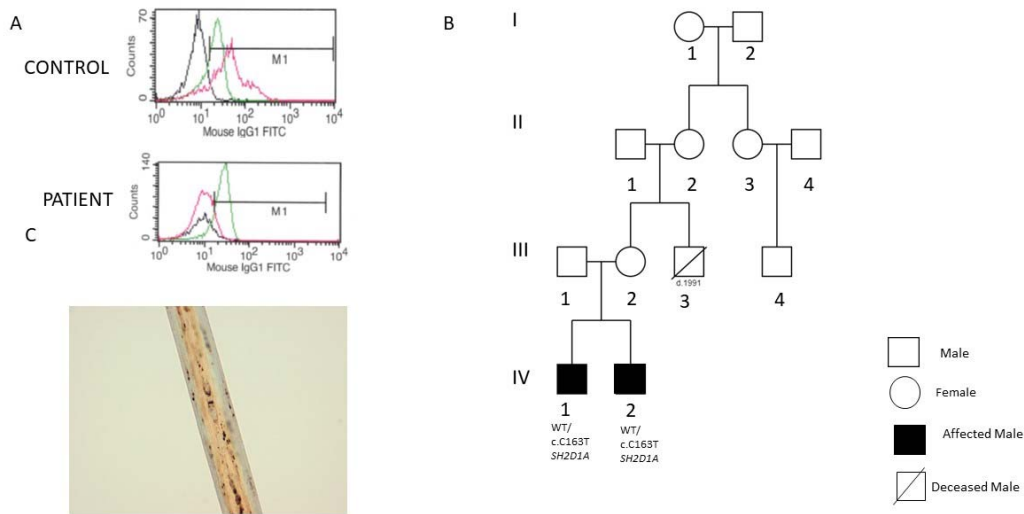
73		F	15	<i>SDHB</i>	c.487T>C	p.Ser163Pro	T/B/A	AD/Het	3	<p>Clinical features: Papilloedema and headaches, raised ICP, arthralgia but no other systemic symptoms</p> <p>Investigations: MRI brain showed white matter insular and frontal cortex lesions. No acute phase response, autoantibodies negative.</p> <p>Treatment: corticosteroids.</p>	Unclassified neuroinflammatory disease
				<i>TRNT1</i>	c.1232T>C	p.Ile411Thr	D/P/D	AR/Het	3		
				<i>C5</i>	c.3029C>T	c.Thr1232Cys	T/D/D	AD/Het	3		
				<i>NOTCH1</i>	c.3836G>A	p.Arg1279His	T/B/D	-/Het	3		
				<i>DNASE1</i>	c.619C>T	p.Arg207Cys	D/D/D	AD/Het	3		
				<i>ACOX1</i>	c.1830A>T	p.Glu610Asp	T/B/D	AR/Het	3		
				<i>RNF213</i>	c.14030G>T	p.Trp4677Leu	D/D/D	-/Het	3		
				<i>PRX</i>	c.4077_4079del	p.Glu1361del	././	AD;AR/Het	3		
74		F	4	<i>MASP2</i>	c.881C>T	p.Thr294Met	D/B/N	AR/Het	3	<p>Clinical features: Raised ICP, right sided sixth nerve palsy and ophthalmological examination revealed papilloedema.</p> <p>Investigations: MRI brain showed bilateral subdural haemorrhages and left sided cortical swelling with involvement of the caudate nucleus and hippocampus and bilateral shallow subdural collections, left being more acute than the right of uncertain aetiology, possibly an acute on</p>	Unclassified neuroinflammatory disease
				<i>TGFBR2</i>	c.1234G>A	p.Val412Met	T/D/D	AD/Het	3		
				<i>HFE</i>	c.829G>A	p.Glu2771ys	D/D/D	AR/Het	3		
				<i>PEX1</i>	c.1380A>C	p.Glu460Asp	T/B/D	-/Het	3		
				<i>COL4A1</i>	c.1673C>T	p.Ala558Val	T/B/D	AD/Het	3		
				<i>IRF8</i>	c.982T>G	p.Phe328Val	D/B/N	AD;AR/Het	3		
				<i>CTCI</i>	c.671G>A	p.Arg224Gln	T/B/N	AR/Het	3		

										<p>chronic process. Repeat scans showed increased ventricular dilatation and persistent filling defect in the right sigmoid sinus thought to represent a non-occlusive thrombus. CT Angiogram - No radiological features to suggest a mid or large vessel vasculitis. No acute phase response, autoantibodies negative, CSF raised neopterin (105nmol/l, RR<65 nmol/l), raised blood lactate at first presentation (7.9 and 4.3), CSF lactate normal, no infection identified.</p> <p>Treatment: dexamethasone and underwent a burr-hole procedure and evacuation of sub-dural haemorrhage.</p>	
75		M	16	<i>MASP2</i>	c.881C>T	p.Thr294 Met	D/B/N	AR/Het	3	<p>Clinical features: Developmental delay, dystonia. No systemic symptoms or other organ involvement</p>	Unclassified neuroinflammatory disease
				<i>PLOD1</i>	c.376T>G	p.Phe126 Val	D/D/D	AR/Hom	3		
				<i>C8A</i>	c.176G>A	p.Arg59Gln	D/D/D	AR/Het	3		

				<i>C8A</i>	c.1742C>G	p.Thr581 Arg	T/P/D	AR/Het	3	Investigations: Bilateral striatal necrosis on MRI brain imaging. Negative autoantibody screen. Negative CSF OGB. Treatment: Nil	
				<i>PTPN22</i>	c.550A>G	p.Thr184 Ala	T/B/D	AD;AR/Het	3		
				<i>RANBP2</i>	c.1730A>G	p.Ala550 Gly	D/B/N	AD/Het	3		
				<i>IFIH1</i>	c.2431A>G	p.Thr811 Ala	D/D/D	AD/Het	3		
				<i>SCN9A</i>	c.1838C>T	p.Pro613 Leu	D/B/D	AD;AR/Het	3		
				<i>SAMD3</i>	c.569T>C	p.Leu190 Pro	D/D/D	-/Het	3		
				<i>SAMD3</i>	c.241C>G	p.Leu81 Val	T/B/N	-/Het	3		
				<i>ELN</i>	c.328G>A	p.Ala110 Thr	D/D/D	AD/Het	3		
				<i>NDUFA1</i>	c.536G>A	p.Arg179 Gln	T/B/N	AR/Het	3		
				<i>CTCI</i>	c.139A>G	p.Lys47G lu	T/D/N	AR/Het	3		
				<i>ATPAF2</i>	c.310T>C	p.Tyr104 His	T/B/D	AR/Het	3		
				<i>RNF213</i>	c.15017C>T	p.Ser5006 Leu	T/B/B	-/Het	3		
				<i>LPIN2</i>	c.2621G>T	p.Cys874 Phe	T/B/D	-/Het	3		
				<i>MEFV</i>	c.442G>C	p.Glu148 Gln	D/D/P	AD;AR/Het	3		
				<i>CFHR5</i>	c.970+2T>G	-	././D	AD/Het	3		
76		M	7	<i>CFHR5</i>	c.1067G>A	p.Arg356 His	T/P/N	AD/Het	3	Clinical features: Recurrent fevers, headaches, arthralgia, loss of memory, seizures.	Unclassified neuroinflammatory disease
				<i>RANBP2</i>	c.7172C>G	p.Thr239 1Ser	T/B/N	AD/Het	3		

				<i>BTD</i>	c.133G>A	p. Gly 45Arg	T/B/N	AR/Het	3	Investigations: MRI brain non progressive white matter disease, normal ESR and CRP, normal SAA, negative autoantibodies. Treatment: corticosteroids	
				<i>TGFBR 2</i>	c.449del	p.Lys153 Serfs*34	././.	AD/Het	3		
				<i>PEX6</i>	c.235G>C	p.Ala79Pro	T/B/N	AD;AR/Het	3		
				<i>POLG</i>	c.158_159ins GCA	p.Gln55_ Pro56ins Gln	././.	AD;AR/Het	3		
				<i>PEX26</i>	c.457C>G	p.Leu153 Val	T/B/N	AD;AR/Het	3		

eFigure. Further Tests in Patients With Isolated Neuroinflammation



eFigure. (A) Absent signaling-lymphocytic-activation-molecule-associated protein (SAP) protein expression in lymphocytes derived from a 3 year old patient with isolated neuroinflammation due to X linked lymphoproliferative disease. (B) Pedigree for family of same patient (IV-1) diagnosed with X linked lymphoproliferative disease due to heterozygous NM_002351:c.C163T (p.Arg55Ter) in the SH2 Domain Containing 1A (*SH2D1A*) gene. His sibling (IV-2) also carried the same mutation. (C) Hair shaft examination from patient 42, showing prominent, diffuse clumps of melanin pigment, typical of Griscelli syndrome. She was identified on NIP to have two variants NM_004580:c.C550T (p.Arg184Ter) and NM_004580:c.G259C (p.Ala87Pro) variants in the Member RAS Oncogene Family (*RAB27A*) gene.