

Supplementary Online Content

Redmond T, O'Leary N, Hutchison DM, Nicolela MT, Artes PH, Chauhan BC. Visual field progression with frequency-doubling matrix perimetry and standard automated perimetry in patients with glaucoma and health controls. *JAMA Ophthalmol*. doi:10.1001/jamaophthalmol.2013.4382.

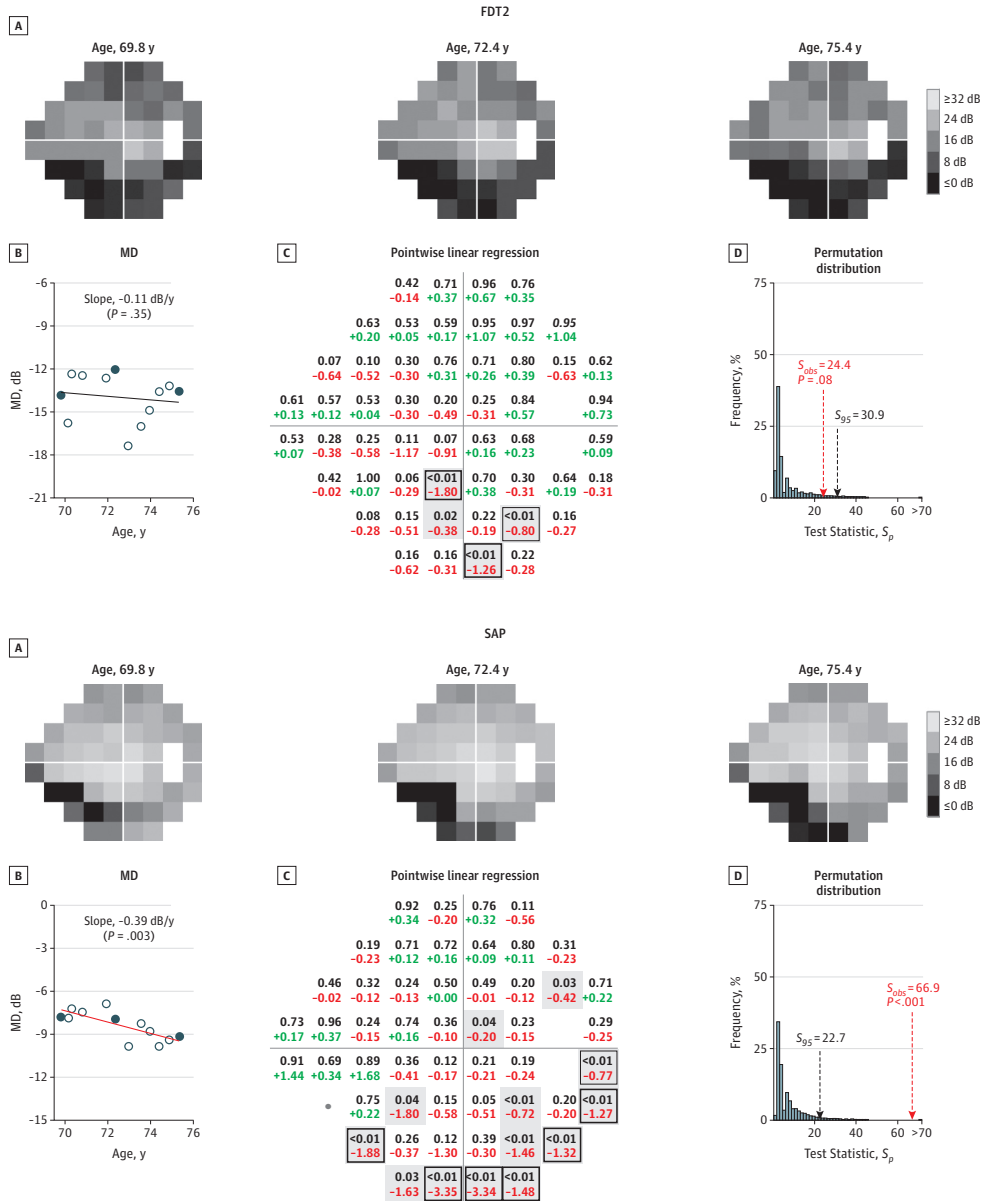
eFigure 1. An example of PoPLR analysis performed on FDT2 (top) and SAP (bottom) with TD data of a glaucoma patient.

eFigure 2. Glaucoma patient (B) with rapid deterioration in the superior visual field that yields statistically significant overall deterioration with both FDT2 and SAP.

eFigure 3. Glaucoma patient (C) with dense visual field loss in the superior visual field.

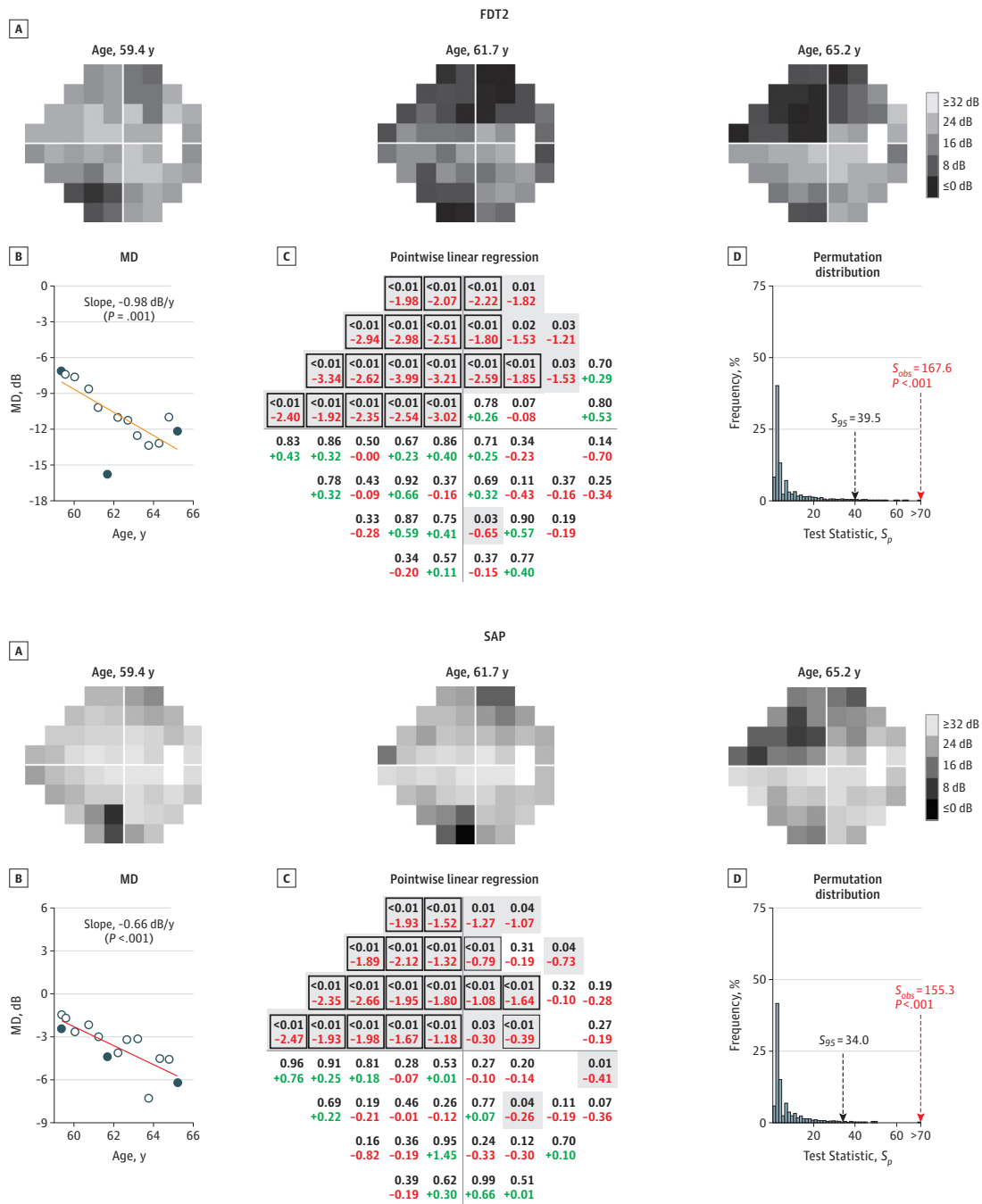
This supplementary material has been provided by the authors to give readers additional information about their work.

eFigure 1. An example of PoPLR analysis performed on FDT2 (top) and SAP (bottom) with TD data of a glaucoma patient.



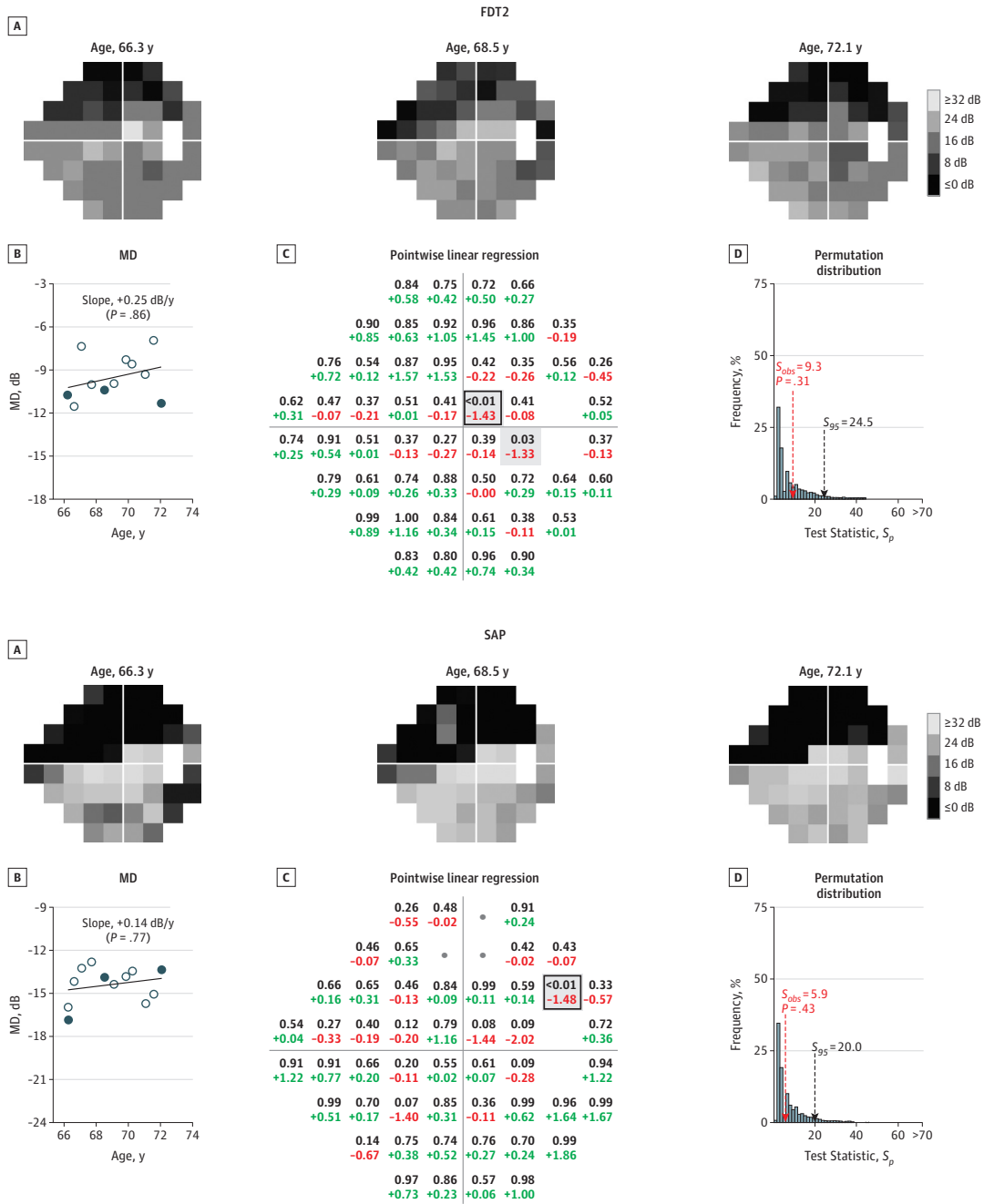
A, Raw sensitivity gray scales of the first, middle, and final examinations. B, The mean deviation (MD) rate and P value. Visual fields in A are represented by a black dot. C, Pointwise linear regression P values (grey) and slopes. Green indicates positive change; red, negative change. Grey shaded regions ($P < .05$) contributed to the test statistic (S_{obs}). The thin black box indicates $P < .01$. The thick black box indicates a rate of change greater than -1 dB/y and $P < .01$. D, Distribution of the combined statistic (S_p) derived from 5000 randomly reordered (permuted) visual field series and its 95th percentile (S_{95} and black arrow). Shown are the observed combined statistic (S_{obs}), its position in the null distribution (red arrow), and the significance value. Deterioration was statistically significant with SAP but not with FDT2.

eFigure 2. Glaucoma patient (B) with rapid deterioration in the superior visual field that yields statistically significant overall deterioration with both FDT2 and SAP.



See the legend to eFigure 1.

Figure 3. Glaucoma patient (C) with dense visual field loss in the superior visual field. Deterioration was not statistically significant with either FDT2 or SAP



Deterioration was not statistically significant using frequency-doubling matrix perimetry (FDT2) or standard automated perimetry (SAP). See the legend to eFigure 1.