# Supplementary Online Content

Shah AS, Prabhu SP, Sadiq MAA, et al. Adjustable nasal transposition of split lateral rectus muscle for third nerve palsy. *JAMA Ophthalmol*. Published online April 10, 2014. doi:10.1001/jamaophthalmol.2014.756.

**eAppendix.**
**eFigure 1.** Pre- (A,C,E,G) and post-operative (B,D,F,H) clinical and high-resolution magnetic resonance imaging of an 8-year-old girl who underwent adjustable nasal transposition of the split lateral rectus (LR) muscle after prior strabismus surgery (Case 1).
**eFigure 2.** Extraocular motility photographs of Case 1.
**eFigure 3.** Extraocular motility photographs of Case 4.
**eFigure 4.** Primary gaze ocular alignment photos of Case 6.
**eFigure 5.** Choroidal effusions from presumed compression of the vortex veins by post-operative day 3 after nasal transposition of the split lateral rectus muscle.

This supplementary material has been provided by the authors to give readers additional information about their work.

## eAppendix.

### *Case 1*

An 8-year-old girl presented with ptosis, exotropia, and a compensatory head posture. She was noted to have an incomplete, left third nerve palsy (sparing the levator muscle) at 2.5 years of age. One year before presentation she had undergone a left lateral rectus (LR) recession of 9.0 mm, left medial rectus (MR) resection of 5.0 mm, and left superior oblique (SO) tendon transposition to the left MR insertion. The deviation was worse after this procedure. On examination, visual acuity was 20/15 in the right eye and 20/60 in the left eye. The patient had complete ptosis of the left eye. Ocular motility was notable for a lack of adduction, elevation, or depression of the left eye, with an exotropia of $35^{\Delta}$ and a left hypertropia of $15^{\Delta}$ at near (eFigure 1A and eFigure 2A). Pre-operative orbital MRI demonstrated attenuation of the superior, medial, and inferior rectus muscles with attenuation of the left posterior cerebellar artery and encephalomalacia. She underwent nasal transposition of the split LR muscle, release of the SO transposition, and a 6.0 mm superior rectus (SR) recession. The superior and inferior poles of the LR muscle were adjusted intraoperatively to produce a small-angle esotropia and no vertical misalignment. She subsequently underwent frontalis sling surgery at post-operative month 8. At post-operative month 11, she had complete limitation of eye movements in all directions. On motility testing there was an 8 prism diopter esotropia (eFigure 1B, eFigure 2B). Post-operative MRI revealed division of the LR behind the globe as each half coursed to the medial aspect of the eye, hugging the scleral wall en route. (eFigure 1C-H).

### *Case 2*

A 1-month-old boy presented with bilateral ptosis and limited eye movements. On examination, he was visually inattentive. Motility showed complete limitation of elevation, depression, and adduction of both eyes with abducting nystagmus. He had an exotropia of 135$^{\Delta}$. MRI of the brain and orbits showed severe hypoplasia of both third nerves and the MR, SR, inferior rectus and inferior oblique muscles of each eye. At 3 months of age, he underwent bilateral frontalis slings (Figure 3A). High-resolution orbital MRI showed attenuation of the superior, medial, and inferior rectus muscles bilaterally with a normal appearing LR muscles (Figure 3C,E). At 7 months of age, he underwent bilateral nasal transposition of split LR muscles, with intra-operative adjustment targeting a small esotropia. At post-operative month 13 he was orthotropic (Figure 3B) with complete limitation of extraocular movements of both eyes. Repeat MRI performed 15 months after the surgery demonstrated splitting of the LR muscles posterior to the globe and redirection of the two halves around the optic nerve towards the insertion of the MR muscle (Figure 3D,F). The alignment remained stable at the most recent post-operative visit 20 months after surgery.

### *Case 3*

An 8-year-old girl with developmental delay presented with complete left third and fourth nerve palsies that she suffered from resection of a cerebellar tumor at 18 months of age. She had undergone a the left MR resection and left LR recession at age 6 years, and she had also been undergone two frontalis sling procedures at ages 18 months and age 5 years. On examination, visual acuity was 20/40 in the right eye and 20/100 in the left eye. Motility testing showed a lack of adduction, elevation, and depression of the left eye.

There was a $30^{\Delta}$ exotropia. She underwent attempted split LR muscle transposition. The LR muscle was found 12 mm posterior to the insertion, and attempted transposition of the muscle showed it could only be brought to the temporal aspects of the superior and inferior rectus muscles. The procedure was aborted, and the LR muscle was recessed an additional 2 mm. The post-operative misalignment improved to $25^{\Delta}$ of exotropia.

### *Case 4*

A 13-month-old boy presented with a congenital, left, near complete, third nerve palsy and compensatory head turn permitting fusion. By 22 months of age, the head turn had diminished due to loss of binocularity, although the ocular misalignment remained stable. On examination, visual acuity was fixes and follows in the right eye and unsteady fixation in the left eye. Motility testing demonstrated a complete lack of elevation and adduction of the left eye. There was a left exotropia of $40^{\Delta}$ and a left hypotropia of $10^{\Delta}$ (eFigure 3A). He underwent nasal transposition of the split LR to the spiral of Tillaux; intraoperative adjustment of the split halves was titrated to leave him slightly esotropic. Immediately after surgery he had a $5^{\Delta}$ esotropia by Krimsky. At the most recent follow-up visit 5 months after surgery motility testing showed no movement of the left eye with no measurable strabismus in primary position (eFigure 3B).

### *Case 5*

A 62-year-old man with a congenital left third nerve palsy and two prior unknown strabismus surgeries at ages 3 and 4 presented to explore options for improved ocular alignment. On examination, visual acuity was 20/20 in the right eye and 20/250 in the left eye. Motility testing showed a trace ability to adduct the eye from an extremely exotropic

position but essentially no motility of the left eye. Deviations testing measured an exotropia of $50^{\Delta}$. He underwent attempted split LR muscle transposition, and the LR muscles was found to be irregular with bands of muscle within connective tissue. The superior aspect of this muscle was less than 2.0 mm wide, and it had little tensile strength. The inferior aspect of the LR muscle was more substantial, but it was very tight disinserted from securing suture during the transposition and retracted posterior to the globe. The procedure was aborted, and the LR muscle was abandoned in the posterior orbit. The exotropia improved from initially to $15^{\Delta}$ but worsened to $70^{\Delta}$ by 5 months after the surgery.

### *Case 6*

A 36-year-old woman presented with a complete third nerve palsy of the right eye. She was well until age 18 when the right eye began drifting outward. At age 23, she was diagnosed with neurofibromatosis type 2. MRI of the brain demonstrated multiple intracranial meningiomas. On examination, visual acuity was 20/125 in the right eye and 20/20 in the left eye. Pupil examination was notable for a dilated, non-reactive right pupil. On motility testing, she had complete limitation of elevation, depression, and adduction of the right eye, with the eye fixed in abduction and a $90^{\Delta}$ exotropia (eFigure 4A). Undilated fundus examination was normal. The patient underwent adjustable nasal transposition of the split LR muscle. Intra-operatively, there was unusual resistance to nasal movement of the eye when the halves of the LR muscle were advanced. The sutures were adjusted intraoperatively to position the eye with a slight esotropia. On post-operative day 3, she was noted to have a $14^{\Delta}$ exotropia and a decline in best-corrected vision to 20/160. Choroidal effusions were noted (eFigure 5). Suture adjustment to reduce the tension on

the globe and vortex veins was considered, but within 3 days the effusions had diminished. Five months after surgery, visual acuity measured 20/70 in the right eye and 20/20 in the left eye. Motility testing showed slight residual abduction and adduction and globe retraction with abduction (Video 2). She had a recurrent exotropia of $40^{\Delta}$ (eFigure 4B). Post-operative high-resolution magnetic resonance imaging of the orbits showed close approximation of the apex of the split of the LR to the globe. Given the globe retraction with attempted abduction, it was hypothesized that the apex of the split attached to the posterior sclera. Nine months after the original surgery, the patient was brought back to the operating room where a lateral orbitotomy was performed. The LR muscle was found adherent to the globe far posterior to the original insertion and still lateral to the optic nerve. The muscle was secured on a suture, detached from the eye as completely as possible, and reattached to the lateral orbital rim. At the same setting, an 10 mm plication of the medial rectus muscle was performed. Two months later, the exotropia measured $45^{\Delta}$ at distance and $35^{\Delta}$ at near; the globe retraction on abduction improved but was not entirely eliminated.

## eFigures.

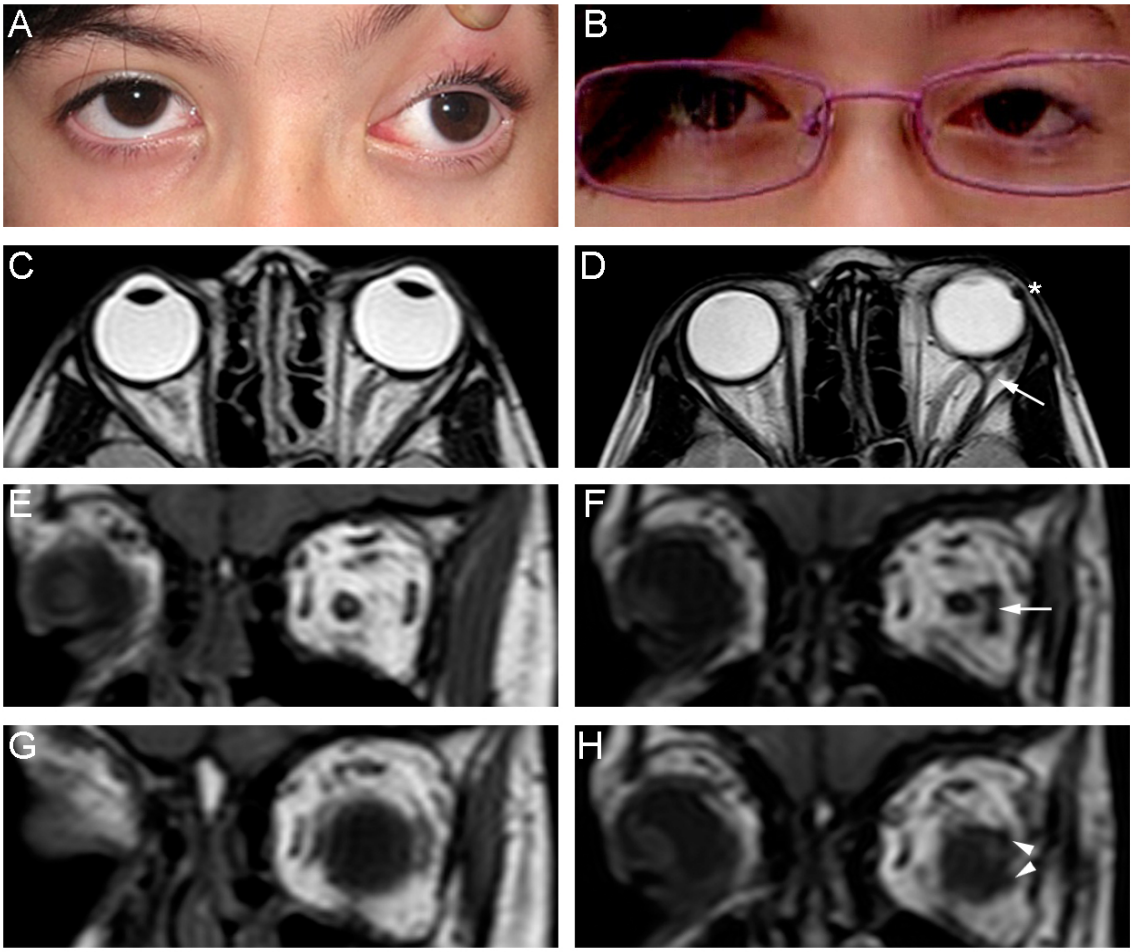


**eFigure 1:** Pre- (A,C,E,G) and post-operative (B,D,F,H) clinical and high-resolution magnetic resonance imaging of an 8-year-old girl who underwent adjustable nasal transposition of the split lateral rectus (LR) muscle after prior strabismus surgery (Case 1). **A, B.** Pre- and 17-month post-operative ocular alignment shows marked reduction in the exotropia. **C, D.** Axial T2 Sampling Perfection with Application-optimized Contrast using different flip angle Evolutions (SPACE) images show the normal position of the lateral rectus (LR) muscle initially (C) and the distal end of the split of the LR (arrow, D). An unknown metallic foreign body is imaged incidentally (*). **E, F.** Coronal T1 images

show the normal course of the LR pre-operatively (E) and the splitting of the LR muscle behind the globe (arrow, F). **G, H.** Coronal T1 mid-globe images show the normal course of the LR along the lateral globe pre-operatively (G) and the inferior and superior LR halves “hugging” the posterior aspect of the globe and travelling nasally (arrowheads, H).

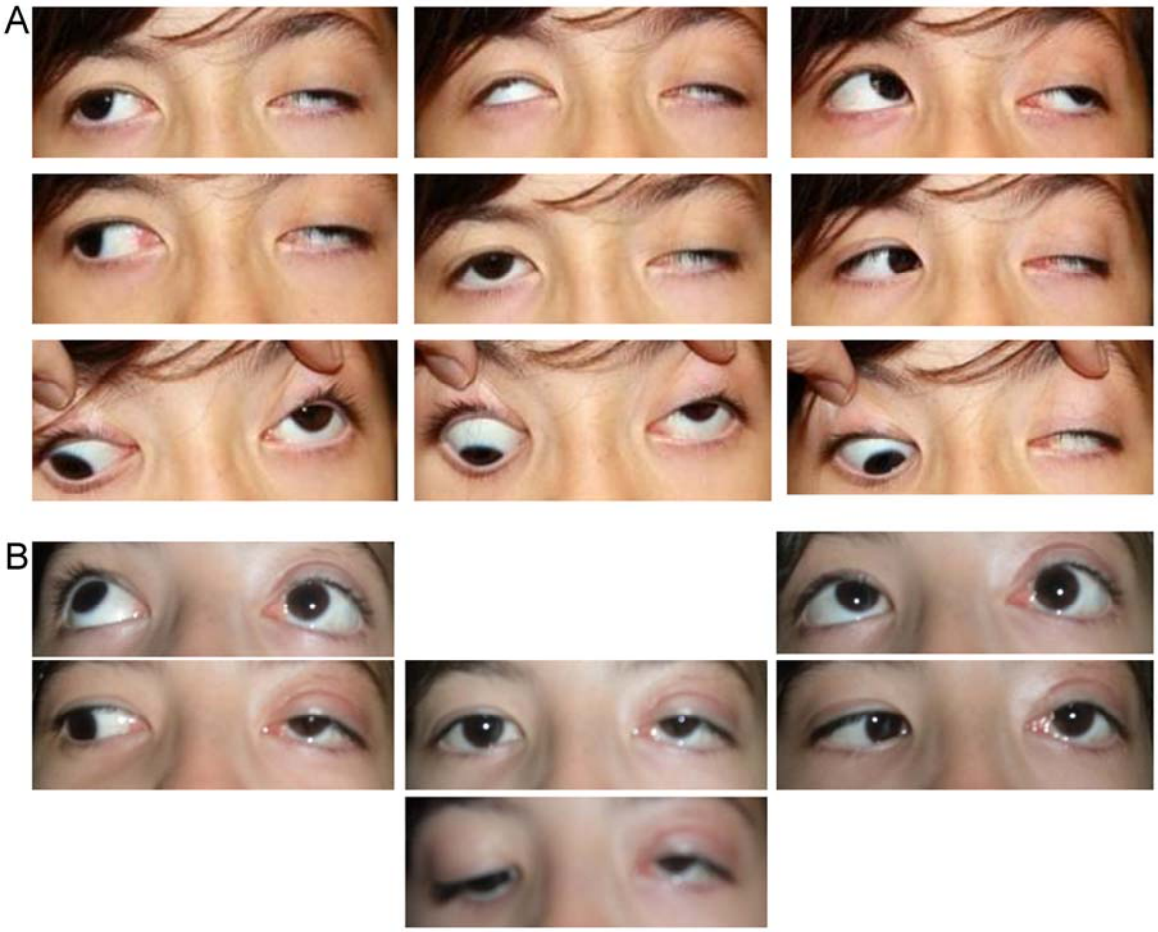


**eFigure 2:** Extraocular motility photographs of Case 1. **A.** Pre-operative photos show near complete ptosis of the left upper eyelid, and a left eye that is hypertropic and exotropic. The left eye shows some abduction best observed in the upper left panel. **B.** Post-operative ocular alignment and extraocular motility photos 11 months after LR muscle surgery and 3 months after a frontalis sling procedure on the left upper eyelid. The middle panel shows a mild left esotropia of 8 prism diopters. The other panels show very little motility to the left eye, but a good reconstructive result in primary position.

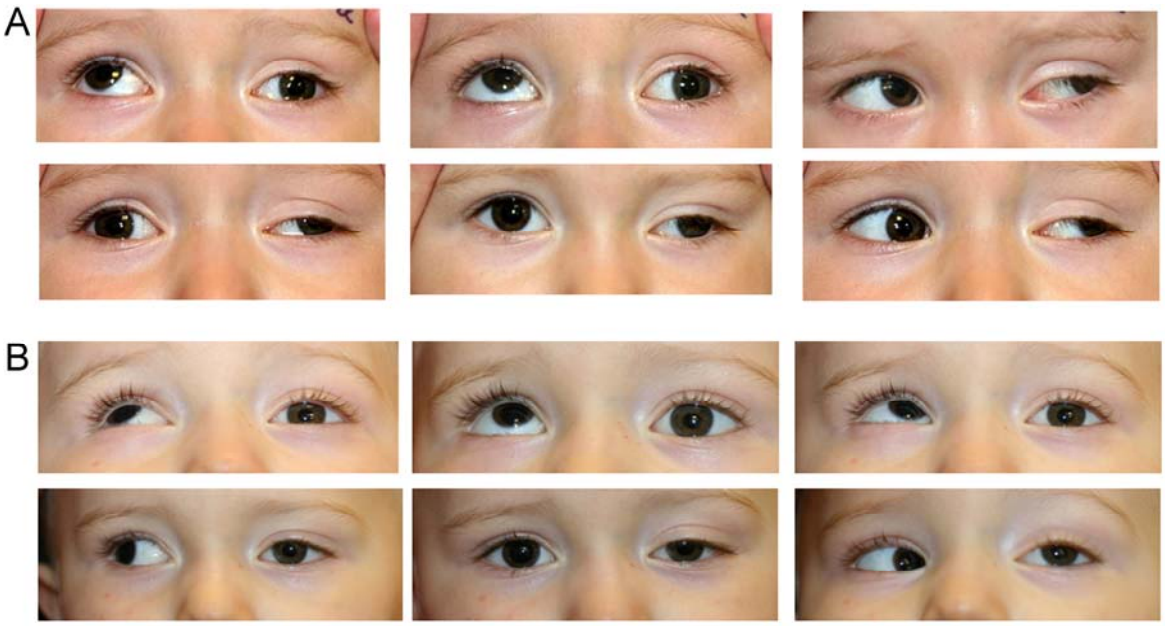


**eFigure 3:** Extraocular motility photographs of Case 4. **A.** Pre-operative photographs show partial ptosis of the left upper eyelid and an exotropia and hypotropia of the left eye. **B.** Post-operative ocular photographs 5 months after transposition of the split LR muscle.

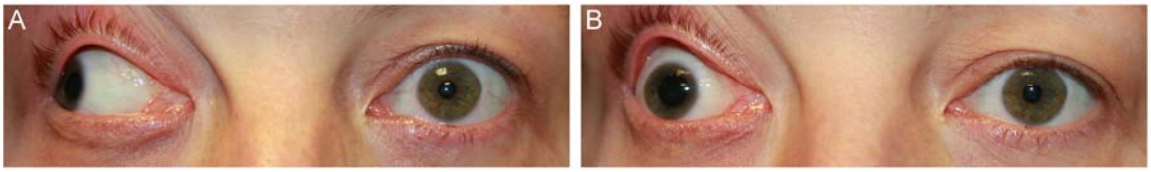


**eFigure 4:** Primary gaze ocular alignment photos of Case 6. **A.** Pre-operative photographs with the right upper eyelid being retracted manually. **B.** Post-operative photographs 4 months after transposition of the split LR muscle.

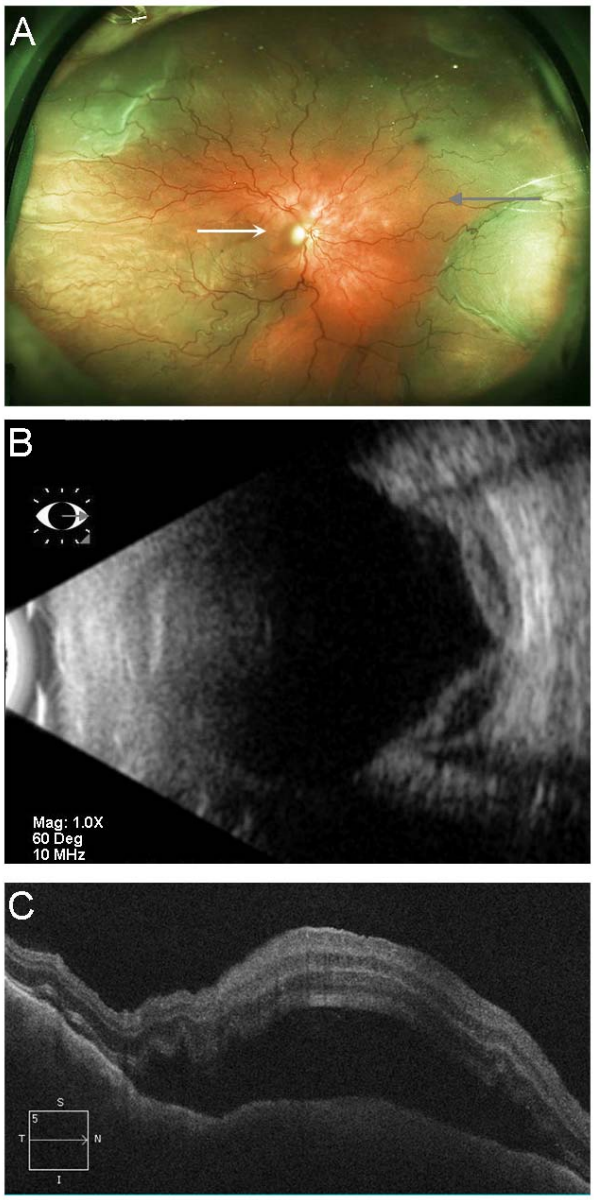


**eFigure 5:** Choroidal effusions from presumed compression of the vortex veins by post-operative day 3 after nasal transposition of the split lateral rectus muscle. **A.** Wide-filed fundus image of the right eye showing peripheral choroidal effusions circumferentially. **B.** B-scan ultrasonography of the nasal posterior segment of the right eye. The gray arrow in (A) shows the direction of the scan with the back of the arrow indicating the top of the ultrasound. C. Optical coherence tomography showing the choroidal effusions extending into the macular region. The white arrow in (A) shows the location of the scan.