Supplementary Online Content

Kubota M, Miyata J, Sasamoto A, Sugihara G, Yoshida H, Kawada R, Fujimoto S, Tanaka Y, Sawamoto N, Fukuyama H, Takahashi H, Murai T. Thalamocortical disconnection in the orbitofrontal region associated with cortical thinning in schizophrenia. *JAMA Psychiatry*. Published online September 3, 2012. doi:10.1001/archgenpsychiatry.2012.1023.

This supplementary material has been provided by the authors to give readers additional information about their work.

eAppendix

Methods 1. Effects of smoking

The possible influence of smoking on brain structure is an important issue. Zhang et al, (2010) reported an additive effect of schizophrenia diagnosis and smoking on the anterior limb of the internal capsule.[1] In contrast, Cullen et al (2012) reported that the apparent effect of smoking may be mediated by IQ.[2] Therefore, in the current study, we examined the effects of smoking on the thalamocortical pathway in cases where a significant group difference in FA was found.

We divided the patient group into never-smoker and smoker sub-groups, and tested for significant differences in FA between these sub-groups using independent sample t-tests. Statistical significance was defined as $p < .05$ (two-tailed).

Methods 2. Quality assessment of MRI images

To eliminate possible artifacts, including gating artifacts,[3] and to guarantee image quality, we performed the following procedures for each participant. For the diffusion-weighted images, nine sets of nine independent directions were acquired, which were all independent of each other. Scanning parameters were properly adjusted for every set. Two or more experimenters visually checked every image at the time of acquisition, and any sets with artifacts were discarded and repeated until images without artifacts were acquired.

Methods 3. Data processing for tract-based spatial statistics (TBSS)

All fractional anisotropy (FA) data were normalized into a common space using FMRIB's Nonlinear Image Registration Tool: normalized FA images were averaged to create a mean FA image, which was then thinned to create a mean FA skeleton, taking only the centers of white matter (WM) tracts common to all the subjects. Voxel values of each subject's FA map were projected onto the skeleton by searching for the local maxima in the direction perpendicular to the skeleton.

Methods 4. Volumetric labeling and surface-based segmentation in FreeSurfer

In the automatic segmentation procedure, each voxel in the normalized brain volume was assigned a label based on an atlas containing probabilistic information about the location of structures,[4] such as the thalamus, caudate, pallidum, putamen, accumbens area, hippocampus, amygdala, cerebral WM, cerebral cortex, brain stem, and non-brain regions. Subdivided cerebral WM regions were then derived from the cortical parcellation.[5]

The cortical surface of each hemisphere was inflated to an average spherical surface to locate the pial surface and the gray matter/white matter (GM/WM) boundary. The entire cortex of each subject was visually inspected, and any topological defects were corrected manually, blind to subject identity. After the creation of cortical representations, all vertices were assigned neuroanatomical labels on a cortical surface model based on the automated labeling systems.[5,6]

Methods 5. Definition of target cortical masks for tractography

Target cortical regions for the probabilistic tractography were extracted from the surface-based procedure in FreeSurfer, based on cortical parcellation.[6] The lateral prefrontal region was defined by merging the rostral and caudal middle frontal, pars opercularis, and pars triangularis regions. The medial prefrontal region was defined by merging the superior frontal, frontal polar, and rostral and caudal anterior cingulate regions. The orbitofrontal region was defined by merging the medial and lateral orbitofrontal regions in addition to the pars orbitalis region, which is considered part of the orbitofrontal cortex.[7,8]

Results. Effects of smoking

Group comparison of FA for the right thalamo-orbitofrontal pathway revealed no significant difference between the never-smoker and smoker sub-groups of patients.

eReferences

1. Zhang X, Stein EA, Hong LE. Smoking and schizophrenia independently and additively reduce white matter integrity between striatum and frontal cortex. *Biol Psychiatry*. 2010;68(7):674-677.

2. Cullen KR, Wallace S, Magnotta VA, Bockholt J, Ehrlich S, Gollub RL, Manoach DS, Ho BC, Clark VP, Lauriello J, Bustillo JR, Schulz SC, Andreasen NC, Calhoun VD, Lim KO, White T. Cigarette smoking and white matter microstructure in schizophrenia. *Psychiatry Res*. 2012;201(2):152-158.

3. Skare S, Andersson JL. On the effects of gating in diffusion imaging of the brain using single shot EPI. *Magn Reson Imaging.* 2001;19(8):1125-1128.

4. Fischl B, Salat DH, Busa E, Albert M, Dieterich M, Haselgrove C, van der Kouwe A, Killiany R, Kennedy D, Klaveness S, Montillo A, Makris N, Rosen B, Dale AM. Whole brain segmentation: automated labeling of neuroanatomical structures in the human brain. *Neuron.* 2002;33(3):341-355.

5. Destrieux C, Fischl B, Dale A, Halgren E. Automatic parcellation of human cortical gyri and sulci using standard anatomical nomenclature. *Neuroimage.* 2010;53(1):1-15.

6. Desikan RS, Segonne F, Fischl B, Quinn BT, Dickerson BC, Blacker D, Buckner RL, Dale AM, Maguire RP, Hyman BT, Albert MS, Killiany RJ. An automated labeling system for subdividing the human cerebral cortex on MRI scans into gyral based regions of interest. *Neuroimage.* 2006;31(3):968-980.

7. Kim DJ, Kim JJ, Park JY, Lee SY, Kim J, Kim IY, Kim SI, Park HJ. Quantification of thalamocortical tracts in schizophrenia on probabilistic maps. *Neuroreport.* 2008;19(4):399-403.

8. Marenco S, Stein JL, Savostyanova AA, , Sambataro F, Tan HY, Goldman AL, Verchinski BA, Barnett AS, Dickinson D, Apud JA, Callicott JH, Meyer-Lindenberg A, Weinberger DR. Investigation of anatomical thalamo-cortical connectivity and fMRI activation in schizophrenia. *Neuropsychopharmacology.* 2012;37(2):499-507.

eFigure 1.
Examples of the seed thalamus (red) and the entire cortical masks (green) in the diffusion space.

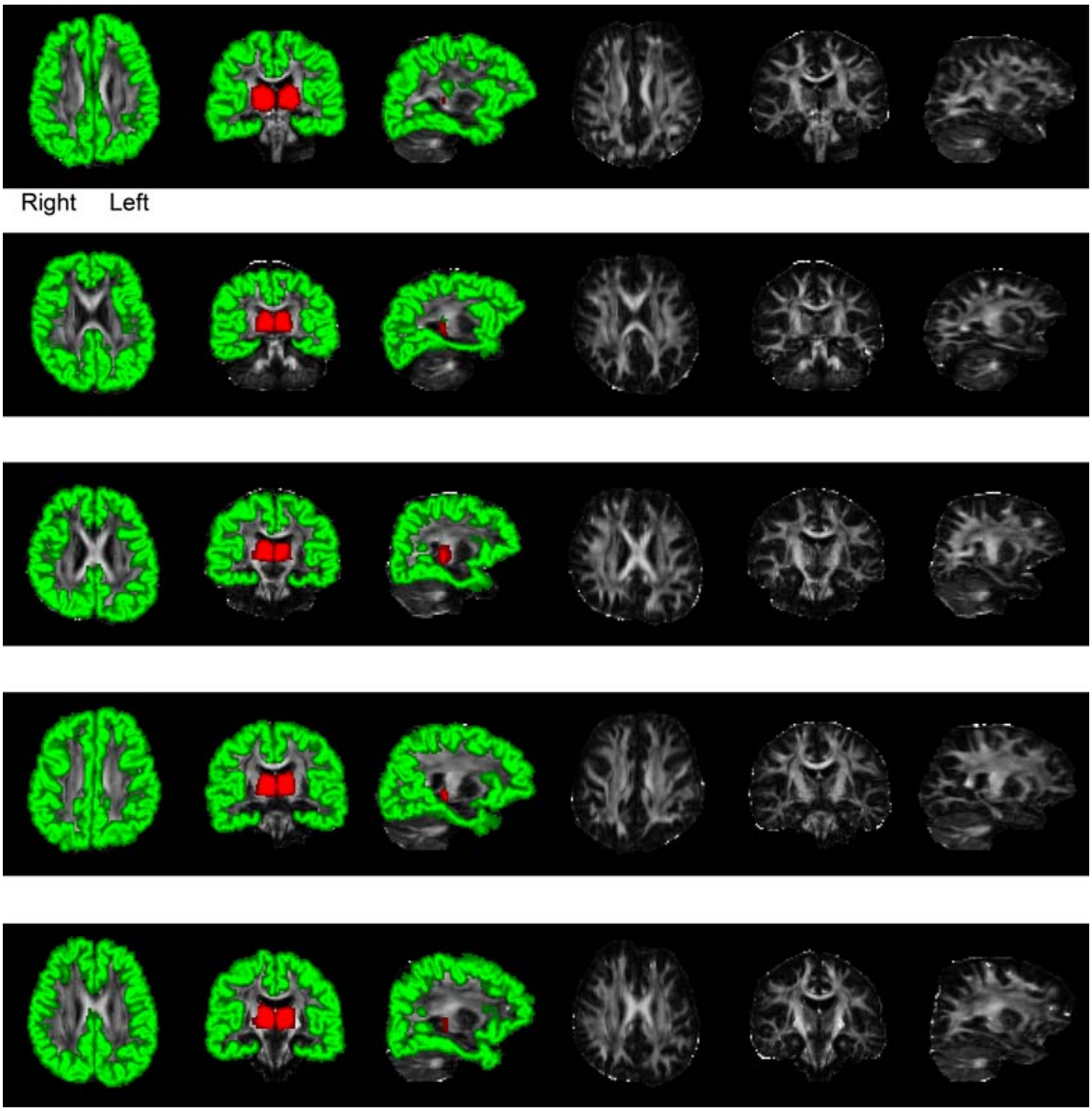

Images are shown with and without the masks to clarify the locations. Left-right orientation is according to radiological convention.

eFigure 2.
Examples of the seed thalamus (red) and the lateral prefrontal masks (light blue) in the diffusion space.

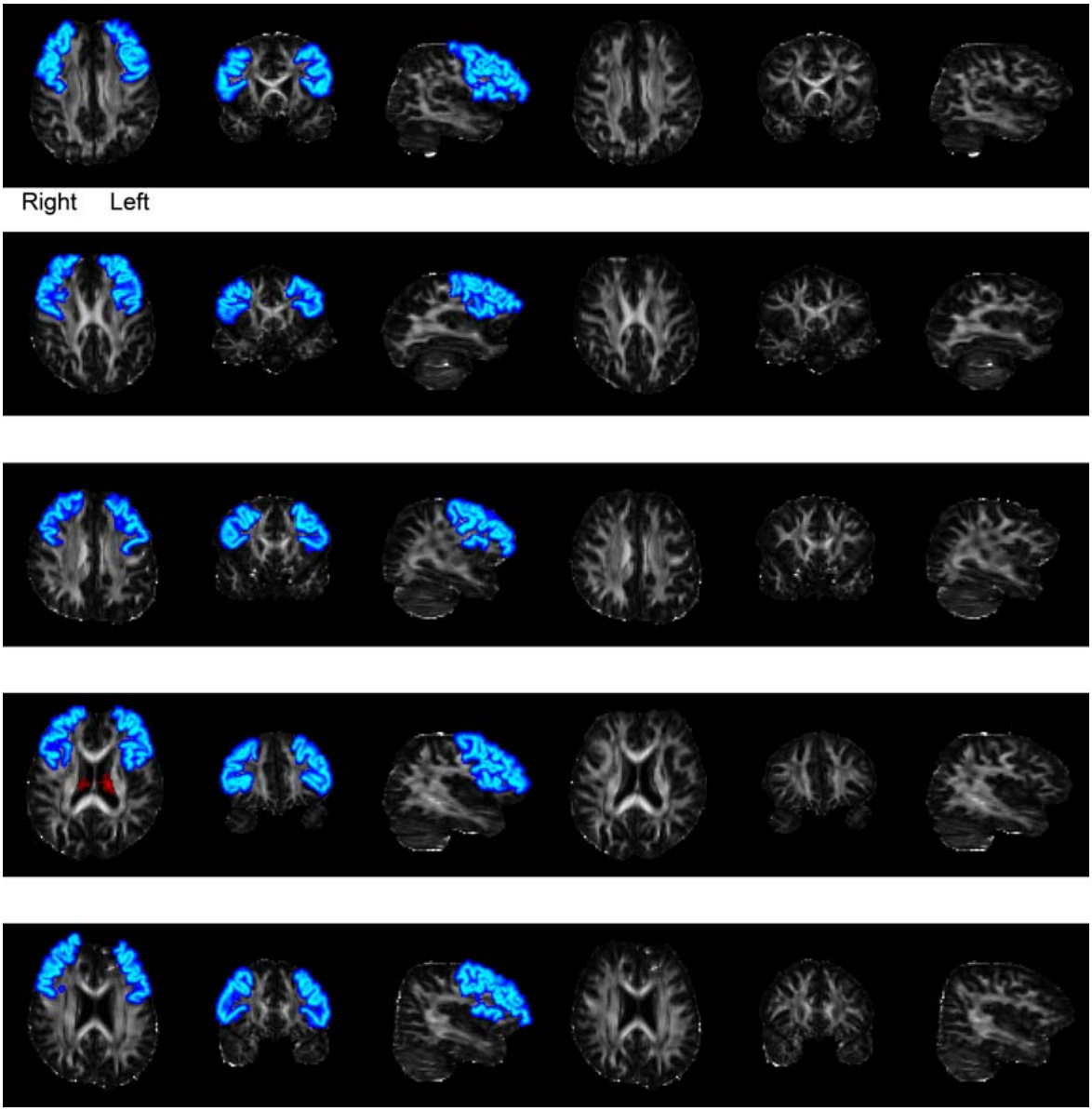

Images are shown with and without the masks to clarify the locations. Left-right orientation is according to radiological convention.

eFigure 3.
Examples of the seed thalamus (red) and the medial prefrontal masks (yellow) in the diffusion space.

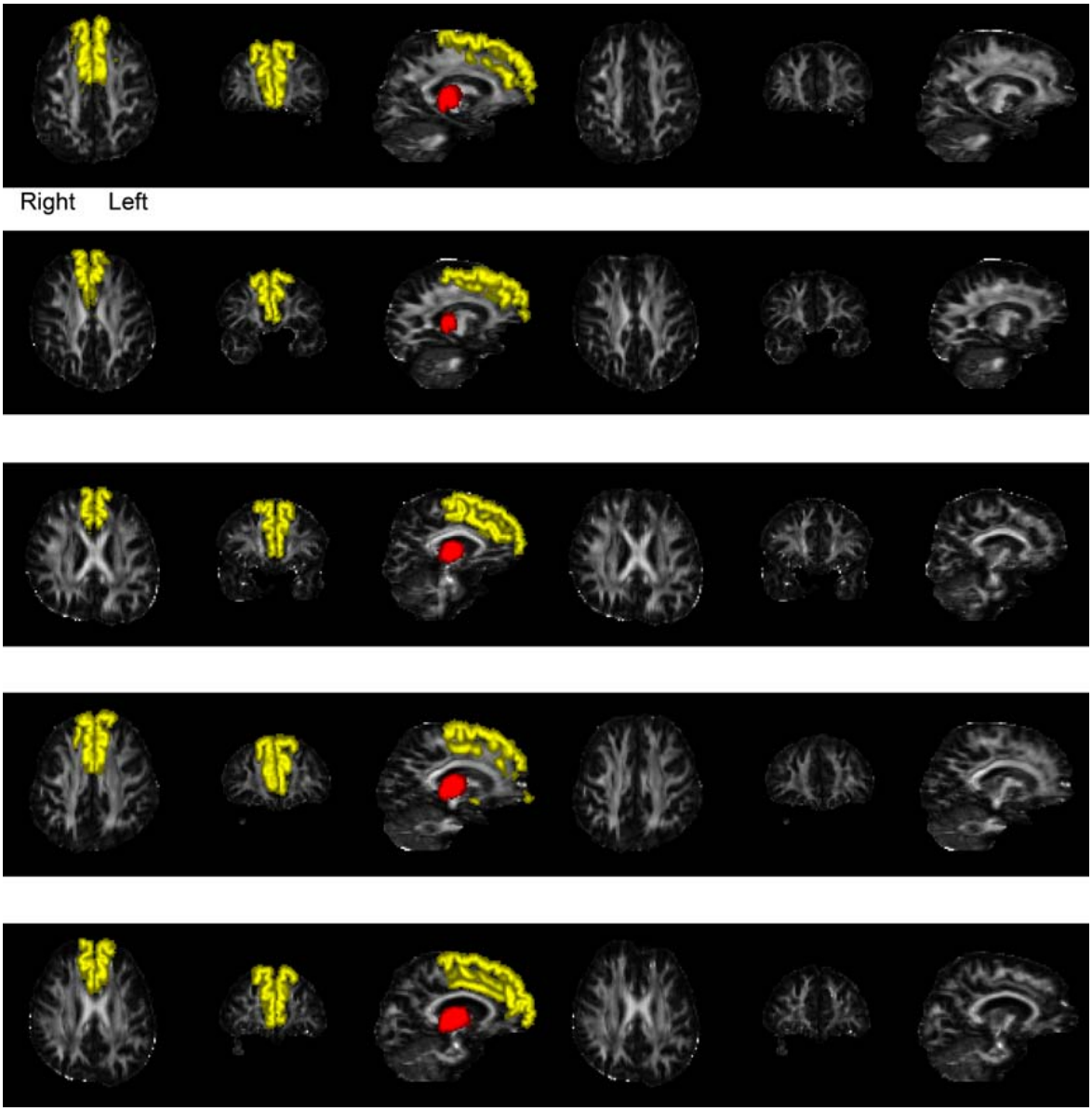

Images are shown with and without the masks to clarify the locations. Left-right orientation is according to radiological convention.

eFigure 4.
Examples of the seed thalamus (red) and the orbitofrontal masks (blue) in the diffusion space.

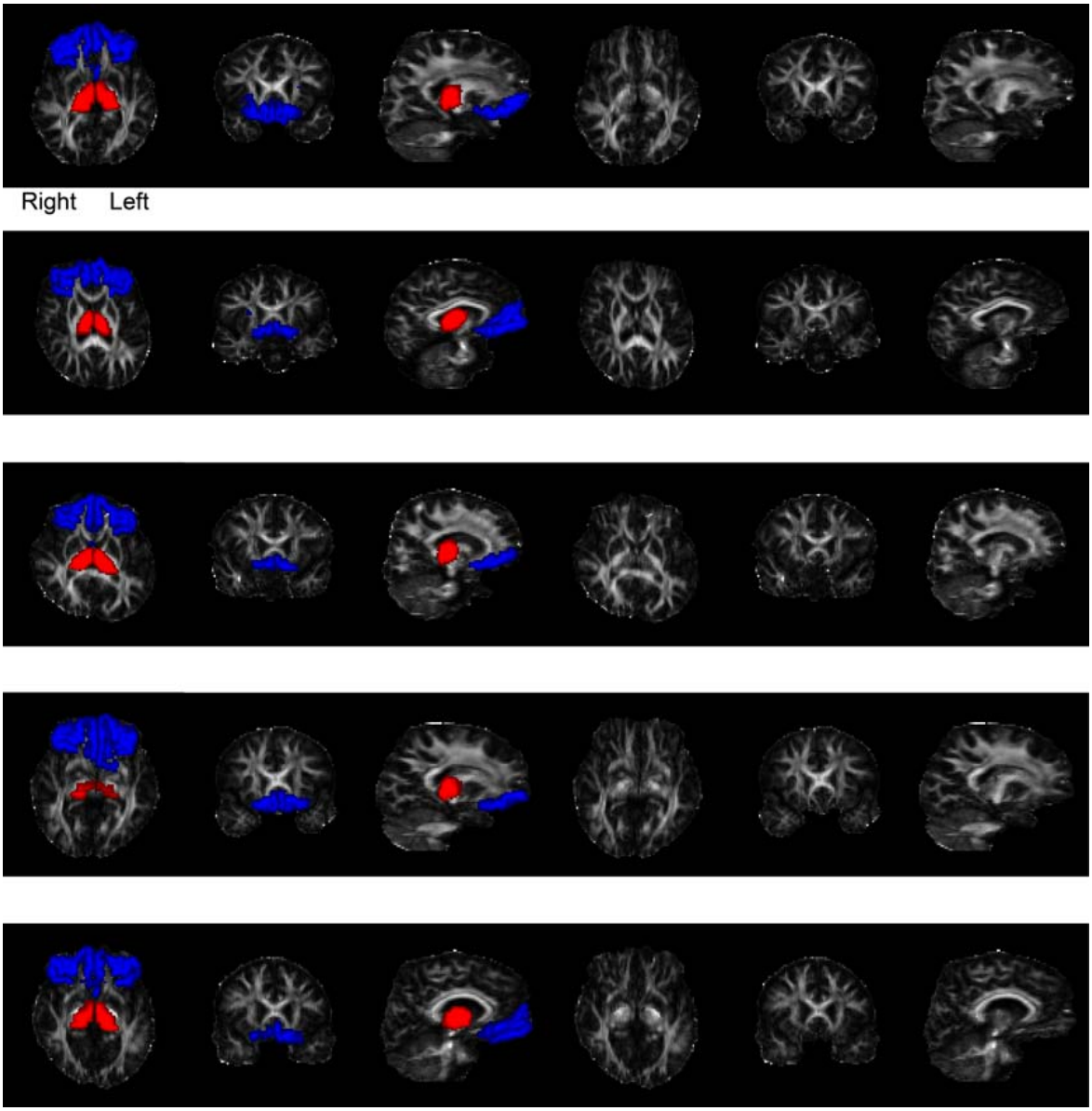

Images are shown with and without the masks to clarify the locations. Left-right orientation is according to radiological convention.

eFigure 5.
Examples of axial slices for b0 and corresponding T1 image.

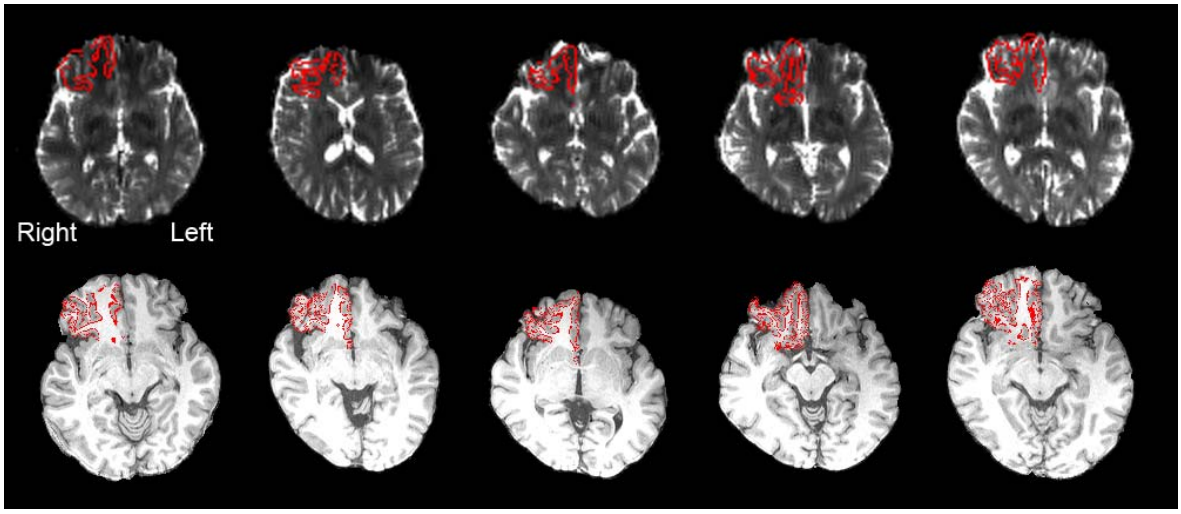

Right orbitofrontal masks are shown with red contours. Left-right orientation is according to radiological convention. The orbitofrontal masks do not cover the frontal tip in some subjects because these regions are included in the medial prefrontal masks.